

Retinal Detachment

Subhadra Jalali MS

Consultant

Smt Kannuri Santhamma

Retina Vitreous Centre

L V Prasad Eye Institute

L V Prasad marg, Banjara Hills

Hyderabad – 500 034

India

Detachment of the retina is a serious event, which may result in complete blindness. The outer segments of the photoreceptors receive oxygen and nutrition from the choroid. If the retina is detached from the choroid, the photoreceptors will fail. The fovea has no retinal blood vessels and depends wholly on the choroid for its oxygen, so detachment of the macula leads to permanent damage to the cones and rods at the posterior pole, and loss of vision. If the macula is not detached, then good vision can be retained if the retina is re-attached promptly.

Types of Retinal Detachment

Retinal detachment (RD) is broadly classified into three types based on the clinical appearance and underlying aetiology.

1. **Rhegmatogenous retinal detachment** (RRD) where the RD develops due to a retinal break ('rhegma', meaning a rent or a fissure) (Figure 1). Fluid, from the vitreous cavity, passes through the retinal break into the potential space under the retina, leading to separation of the retina from the underlying choroid. This requires surgical treatment.
2. **Tractional retinal detachment** (TRD) which occurs due to pre-retinal membrane formation and scarring that pulls the retina from its attachment. This may require surgery depending on the extent of the RD. The commonest causes of

TRD are diabetes, Eales's disease, sickle cell retinopathy and trauma.

3. **Exudative and serous retinal detachments** occur due to abnormalities in water transport across the bed of the retina (retinal pigment epithelium) or in its blood supply.

Tractional and exudative/serous retinal detachments are less common and will not be discussed in this paper.

Symptoms and Signs

The commonest presenting symptom of RD is sudden, painless loss of vision or blurring of vision in the affected eye. Some patients with partial RD notice field loss, i.e., loss of vision in only one part of the visual field and describe this as a veil or shadow in one area of their vision. Flashes and floaters may occur in the affected eye a few days or weeks before the loss of vision. This is due to vitreous degeneration and its traction on the retina. Inferior retinal detachments can often be silent and slowly progressive so that the onset of RD goes unnoticed until it reaches the posterior pole. Sometimes RD is accompanied by mild discomfort and redness due to associated uveitis and hypotony, and this may be mistakenly diagnosed as idiopathic anterior uveitis. In children and young adults, RD may be asymptomatic initially and is diagnosed only after the affected eye develops squint, or redness, or a white pupillary reflex due to rapid progression of cataract.

In developing countries, retinal detachment frequently presents late, and this means that the macula is detached in approximately 90% of eyes at presentation. Patients are more likely to have scarring and fibrosis of the retina, and other problems associated with long-standing retinal detachment. Because the abnormalities that caused the detachment are often bilateral, up to a third of patients may be blind in their other eye at presentation – often because of untreated retinal detachment.¹

Diagnosis of Retinal Detachment

The best method of diagnosing RD is by binocular indirect ophthalmoscopy with scleral indentation. An obvious RD is recognised by loss of the red fundus reflex and marked elevation of the retina (Figure 1). The retina appears grey, and shows folds and undulations. Shallow detachments are difficult to diagnose but

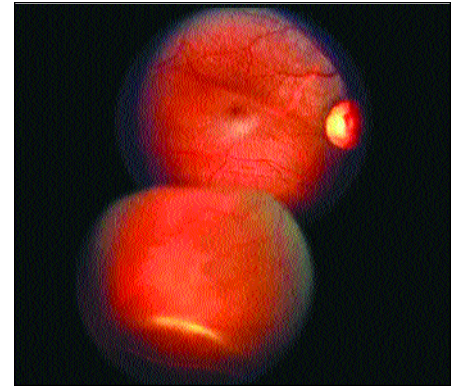


Fig. 2 Shallow retinal detachment with traumatic dialysis misdiagnosed as serous macular detachment due to central serous retinopathy – can be managed by simple scleral buckling

Photo: Subhadra Jalali

can be seen with stereoscopic visualisation of the retinal vessels that cast a shadow on the underlying retinal pigment epithelium (Figure 2).

It is important to assess the state of the macula. If the macula is still attached, this is a medical emergency, and the patient should have surgery within 24 hours in order to prevent macular detachment and permanent loss of vision. If the macula is already detached, then surgery should be carried out within a week or two.

In eyes with opaque media, ocular B-scan ultrasonography is useful for diagnosing RD and associated pathology, like proliferative vitreoretinopathy (PVR), intraocular foreign bodies, etc. Ultrasonography also rules out many lesions associated with exudative retinal detachments such as tumours, posterior scleritis, etc.

Predisposing Causes

Although RD can occur in any eye, certain eyes are predisposed to develop detachment. The risk factors are given in Table 1. All eyes that are predisposed to RD should undergo periodical, dilated retinal examination (including the retinal periphery by scleral depression), to detect any retinal breaks/areas of lattice degeneration, that can predispose to RD. Early detection of some of these conditions can give an opportunity for prophylactic treatment.

Management

Most retinal detachments progress to total retinal detachments and complete loss of vision. If the retina is not re-attached promptly (usually less than a week after macular detachment), then visual recovery is progressively affected. Also, long-standing retinal detachments start to develop scarring, called 'proliferative vitreoretinopathy' (PVR) that can prevent re-

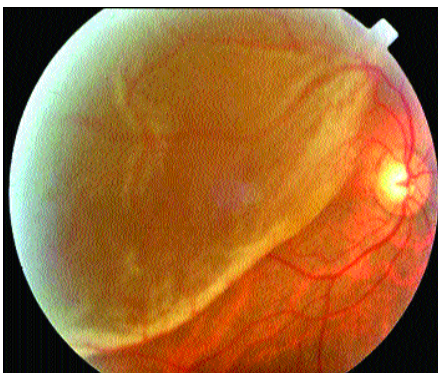

Fig 1: Recent subtotal rhegmatogenous retinal detachment

Photo: Subhadra Jalali

Table 1: Risk Factors for Rhegmatogenous Retinal Detachment*

1. Axial myopia.
2. Post cataract surgery (aphakia/pseudophakia) especially if the posterior capsule is ruptured during surgery and/or there is vitreous loss.
3. Yag laser capsulotomy.
4. Lattice degeneration of the retina.
5. Symptomatic (flashes/floaters) retinal tears.
6. Ocular trauma.
7. RD in one eye.
8. Family history of RD.
9. Certain genetic disorders such as Marfan's syndrome, Stickler's syndrome.
10. Pre-existing retinal diseases like coloboma choroid, retinoschisis.
11. Following acute retinal infections as in acute retinal necrosis syndrome (ARN) or CMV retinitis.

* Excludes causes that result in combined rhegmatogenous and tractional retinal detachment

attachment. Besides PVR changes, chronic retinal detachments can develop other complications such as hypotony, pigmentary glaucoma, new iris vessels, cataract and uveitis, which can compromise visual outcome. Rarely, the detachment does not progress, either due to spontaneous closure of the retinal break or by development of demarcation lines.

The principle of retinal re-attachment surgery is to close all the retinal breaks and create strong chorioretinal adhesions so that these breaks do not open and new breaks do not occur.

Two approaches are established to achieve this objective. One is an external approach using scleral indentation with silicone material called 'scleral buckling'. This approach needs minimal instrumentation and materials, and is widely available. It is suitable for uncomplicated forms of retinal detachment, with a high success rate. However, this surgery is not appropriate for complicated retinal detachments such as those with PVR (Figures 3a, 3b), giant retinal tears, coloboma choroid, penetrating ocular trauma, etc.

In these situations, an internal approach called 'vitrectomy' is used. This requires expensive and complex equipment and is available in few centres in developing

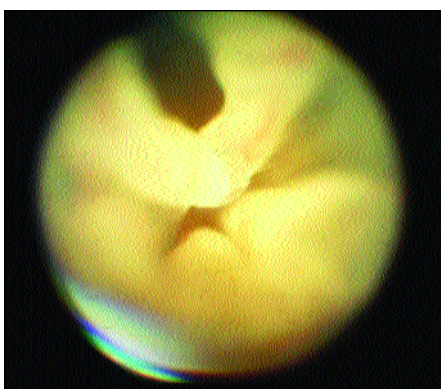


Fig. 3a: Chronic retinal detachment with advanced PVR and large horse-shoe tear

Photo: Subhadra Jalali

countries. However, vitrectomy techniques have revolutionised retinal detachment surgery, giving a higher rate of successful re-attachment than previously.

Results of Treatment

RD is no longer an incurable condition. Surgical results have improved considerably in the last two decades.^{2,3} In developing countries, the final re-attachment rates vary from 77–87% with the use of modern technology.¹ The anatomical success depends on a variety of factors including the type of retinal detachment, age of patient and surgical expertise. Unfortunately, visual results do not always match the anatomical success. If the macula has been detached for a long time, central vision will not be regained, however, the patient will usually obtain useful navigational vision. In India, 80% of successfully re-attached retinas obtained a vision of 6/60 or better.¹

Prophylaxis

It is important to prevent RD, since 5–15% of retinal re-attachment operations are unsuccessful and only 55–60% eyes with re-attached retinas get good visual outcomes.^{3,4} Also RD surgery is more expensive than prophylactic treatment and can be associated with serious complications. Most rhegmatogenous RDs are due to retinal tears that occur from vitreoretinal traction in areas of abnormally firm vitreoretinal adhesions. Exceptions are post-traumatic tears and round holes in areas of lattice degeneration in myopic eyes of young patients. Prophylactic treatment aims to create strong chorioretinal adhesions in areas of retinal tears or areas of strong vitreoretinal traction. Visible lesions that could be considered for prophylactic treatment include:^{4,5}

1. Horseshoe tears (high risk of progression to RD without treatment).

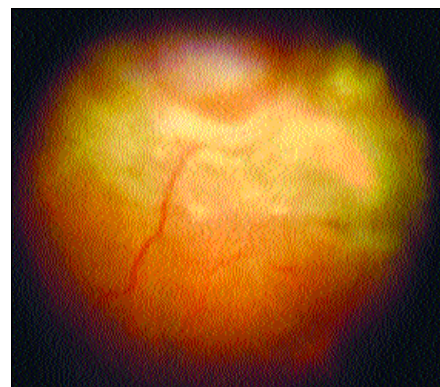


Fig. 3b: Same eye after re-attachment surgery with vitrectomy and silicone oil injection

Photo: Subhadra Jalali

2. Lattice degeneration with or without holes and with or without vitreous traction (risk of progression uncertain).

To 'treat or not to treat' depends on other factors that predispose to a high risk of retinal detachment (Table 1) and on the known complications of prophylactic treatment. Methods of prophylactic treatment include cryotherapy, laser photocoagulation and, very rarely, prophylactic scleral buckling.

Conclusion

Retinal detachment is a vision threatening condition that requires early surgery. It can be diagnosed best by retinal examination using indirect ophthalmoscopy. Treatment outcomes have improved with modern surgical techniques, but the key to successful re-attachment is early detection and prompt referral by primary eye care workers. More widespread availability of trained human resources and equipment is essential to manage and prevent retinal detachments that can cause unilateral and, not uncommonly, bilateral permanent blindness.

References

- 1 Yorston D, Jalali S. Retinal detachment in developing countries. *Eye* 2002; **16**: 353–358.
- 2 Thompson J A, Snead M P, Billington B M, Barrie T, Thompson J R, Sparrow J M. National audit of the outcomes of primary surgery for rhegmatogenous retinal detachment. *Eye* 2002; **16**: 771–777.
- 3 Johnson Z, Ramsay A, Cottrell D, Mitchell K, Stannard K. Triple cycle audit of primary retinal detachment surgery. *Eye* 2002; **16**(3): 513–518.
- 4 Wilkinson CP, Rice TA. Prevention of retinal detachment. In: Michel's Retinal Detachment, 2nd edition. 1997; pages 1128–1133.
- 5 Hilton GF, McLean EB, Chuang EL. Retinal Detachment. Ophthalmology monograph, American Academy of Ophthalmology, 5th edition. 1989; pages 89–95.

☆ ☆ ☆