



Vernal keratoconjunctivitis



Anthony Hall
Head of
Department



Bernadetha Shilio
Consultant
Ophthalmologist

Department of Ophthalmology, Kilimanjaro Christian Medical Centre, PO Box 3010, Moshi, Tanzania.

Why is allergic eye disease a problem for eye workers?

Why is allergic eye disease, and vernal keratoconjunctivitis (VKC) in particular, a problem for eye workers and patients in hot climates?

A large number of children are affected

Over a quarter of 2,250 children seen at a tertiary referral paediatric eye clinic in East Africa had vernal keratoconjunctivitis. Even more came flocking to screening clinics complaining of itchy eyes.

This is time consuming and frustrating

Typically a child seen with VKC is given one bottle of a mast cell stabiliser and is seen again a few months later apparently no better. Alternatively steroids are used, without a mast cell stabiliser and no counselling about the disease. Quite often children move from one clinic to another picking up another bottle of steroids when the symptoms become unbearable. Both patient and clinicians are frustrated. Over 50% of patients may still have symptoms after five years.¹

Patients may be blinded by the disease (Figure 4)

Up to 10% of patients develop corneal ulcers, which may lead to visual loss due to corneal changes. The figure may be higher in hotter climates. Other patients will have visual impairment due to glaucoma and cataract² or extensive cornea pannus (Figure 2 and Figure 6).

How can this frustrating situation be improved?

- 1 By recognising the features of the disease, particularly potentially blinding complications.
- 2 Ensuring that these patients get adequate continuous treatment through good patient education and regular, long-term follow-up.

Recognising the disease: clinical features

VKC is a bilateral chronic inflammation of the conjunctiva. It is more common in young boys. The disease affects children between three to 16 years of age though it may appear earlier than that and continue into adulthood (Figure 1). In the majority of cases, symptoms resolve at puberty. Although the name vernal suggests a seasonal spring time occurrence, frequently the disease persists throughout the year.

Symptoms

Symptoms include intense itching, irritation, photophobia (sensitivity to light) and burning. The itching is worse with exposure to wind, dust, bright light and hot weather. Some patients complain of a sticky, stringy mucous discharge. Corneal involvement leads to complaints of reduced vision.

Signs

In order to elicit the signs, patients should be examined using a slit lamp or magnifying loupes. The use of fluorescein will help to identify sight threatening corneal involvement. The disease is characterised by giant papillae. In the palpebral form, giant, flat-topped papillae of the upper tarsal conjunctiva lead to a clinical picture of 'cobblestones'. Corneal involvement has been reported in as many as 50% of the patients with the palpebral type of the disease. Corneal involvement may range from superficial punctate keratopathy to shield-like ulcers.² These may heal leaving a vascularised scar.

The limbal form is more common in dark-skinned races and females. It is characterised by conjunctival hyperaemia and papillae at the corneal-scleral (limbal) border and Trantas' dots. The latter are aggregates of epithelial cells and eosinophils. A gelatinous pannus may

Anthony Hall

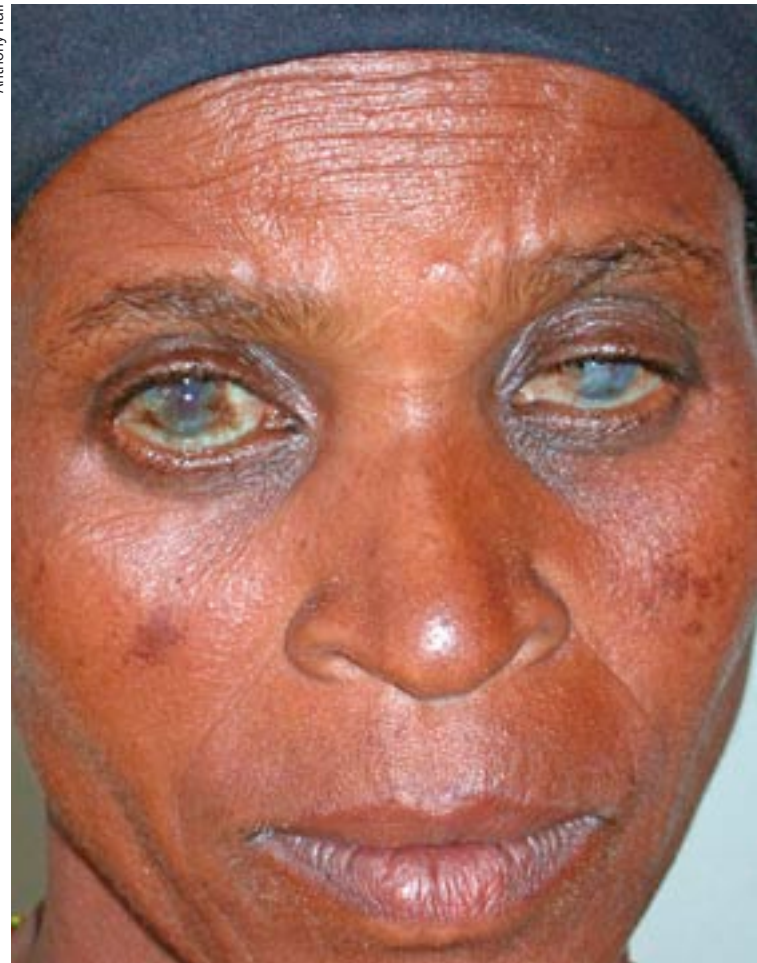

Fig. 1. Adult with long standing severe vernal keratoconjunctivitis (VKC)

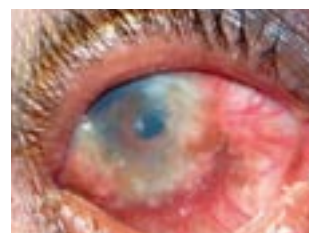

Fig. 2. Right eye of patient in figure 1

Note the dilated, injected conjunctival vessels, Trantas' dots, and corneal scarring and vascularisation. The white tissue in the nasal portion of the pupil is posterior capsule opacification, following cataract surgery.

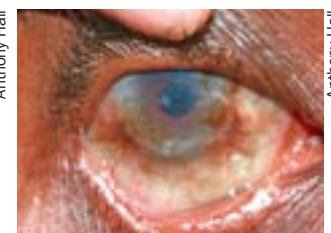

Fig. 3. Right eye of patient in figure 1

One week after supratarsal triamcinalone injection: the eye is quiet and comfortable with resolution of all signs of inflammation.

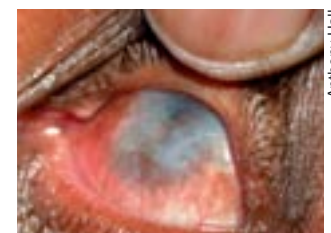

Fig. 4. Left eye of patient in figure 1

Blinding VKC corneal scarring and vascularisation.

'Individual counselling backed up by patient information leaflets is critical in breaking the cycle of inadequate treatment of vernal keratoconjunctivitis'

invade the cornea (Figure 6). Neovascularisation of the cornea may follow (Figure 4). Conjunctival changes include hyperpigmentation (Figure 2), subconjunctival fibrosis, keratinisation and symblepharon.

Visual impairment is more pronounced in cases with shield ulcers and corneal plaques. The clinician also needs to be constantly on the lookout for the other major complications of cataract and glaucoma especially with prolonged steroid use.

Providing adequate continuous treatment

Counselling

Once the severity of the disease has been characterised, a treatment plan is devised.

We examine and counsel the many children coming to the free district eye clinics in groups. Those with no signs of allergic eye disease are given advice on frequent face washing and cold compresses. They should not be given a bottle of steroid or chromoglycate drops, tempting as this might be. Unnecessary drops can make the situation worse (Figure 7).

Children with signs of allergic eye disease and those presenting to the tertiary referral centre who tend to have more severe disease are examined in more detail and counselled individually. Individual counselling, backed up by patient information leaflets, is critical in breaking the cycle of inadequate treatment and resulting frustration.

Counselling stresses the chronic nature of the disease, that sodium chromoglycate drops take time to work and need to be continued once the child feels better. Children getting steroid drops are told to use these frequently initially. The need to use these for only a short period of time in order to avoid complications is explained. The majority of children and parents respond well to this counselling. As a result, many patients return for review before drops have run out and the symptoms and signs worsened. The use of a dedicated counsellor will save the busy clinician valuable time.

Drug treatment

Treatment is symptomatic and tailored to the severity of the disease.

Those with milder symptoms and no corneal involvement may be given mast cell stabilisers such as sodium chromoglycate or newer agents such as alomide and nedocromil. (If you have access to a low-cost drop manufacturer you can ask for 4% sodium chromoglycate for more severe cases). Topical antihistamines are effective as well.

The mast cell stabilisers must be used regularly three to four times daily, even when there are no symptoms in order to stabilise the mast cells and prevent the release of histamine. They are of no value when used only when

symptoms occur because their effect is not immediate. If well used, they can limit or stop the use of steroid drops. They do not have any of the side effects of steroids and can therefore be used for a prolonged period.

Those presenting with corneal involvement and more severe disease should be managed at secondary and tertiary level where they may be given topical steroid drops (e.g. prednisolone, dexamethasone), the most effective available topical medication for severe vernal keratoconjunctivitis. A mast cell stabiliser should be started when the steroids are started. Steroids should be used frequently initially and then tapered to a stop once the acute stage of the disease is stabilised (usually a few weeks). Their use requires monitoring because of the possible effect on intraocular pressure.

Those not responding to conventional treatment may be given supratarsal injection of steroids⁴ by an eye specialist (Figure 5). Both long-acting steroids such as triamcinolone and shorter-acting steroids (dexamethasone) have been found to be effective in bringing about resolution of the eye signs. Some studies suggest that the recurrence rate of the disease is lower following the use of longer-acting steroids like triamcinolone. Theoretically there is an increased risk of persistent elevation of intraocular pressure with the longer acting steroids. In children, these injections often need to be administered under general anaesthesia. However, with good use of local anaesthesia and careful counselling, children as young as 12 may be safely injected without recourse to general anaesthesia (Figures 8 - 10).

Cyclosporine A drops (0.5-2%) in olive oil or castor oil four times a day are an effective alternative to steroids in severe VKC, if available.⁵

Cryotherapy of the palpebral conjunctiva may produce additional inflammation with little benefit.²

Debridement of early mucus plaques may speed repair of the persistent epithelial defects. Bandage contact lenses are helpful in the treatment of these defects.

Supportive therapy like artificial tears, cold compresses and sunglasses often help and are commonly overlooked.

Drug allergies

Allergic reaction in the conjunctiva can be provoked by a drug or its preservative. Common drugs include neomycin and gentamicin. These are common in postoperative drops. When examined, the conjunctiva and the lower eyelids will be swollen. The skin may be excoriated. The first measure in the management is to stop using the allergen. Topical steroids may also be used to relieve the symptoms. Far too often the offending drug has been given for a minor symptom because the patient expects drops. This often does more harm than good (Figure 7).

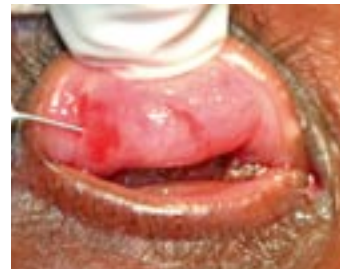

Fig. 5. Technique of supratarsal injection

Note the needle is parallel to the superior tarsal border – entering from the temporal side.

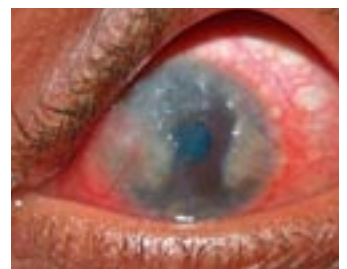

Fig. 6. Child with severe limbal VKC

Note the marked conjunctival hyperaemia, Trantas' dots and invasion of cornea by thickened gelatinous pannus.

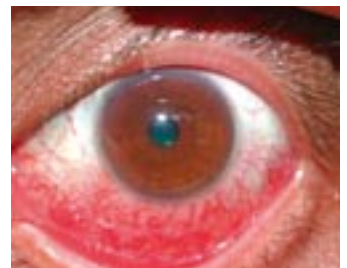

Fig. 7. Drug induced allergic conjunctivitis

This man was seen at a health centre complaining of itchy dry eyes. He was given gentamicin and prednisolone drops which he used continuously for three weeks. He came to us complaining that the eyes were now red and sore and felt worse when the drops were put in. Note the conjunctival hyperaemia in the lower half of the eye. The upper half is white and quiet.

Continues over page ➤

Before

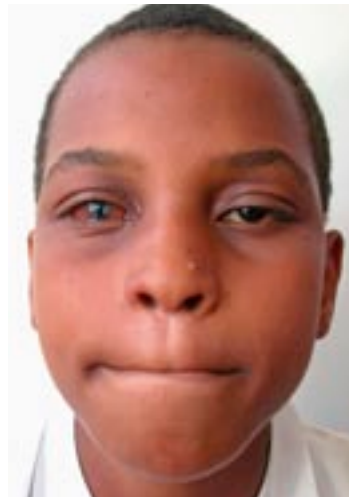

Fig. 8.

After

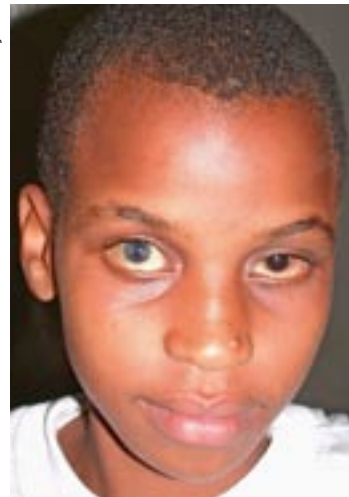

Fig. 9.

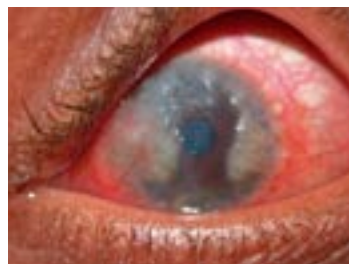

Fig. 10.

Fig. 8.

13 year old girl with predominantly unilateral severe limbal vernal keratoconjunctivitis. Note the lid swelling, increased skin pigmentation around the lid and the injected conjunctiva. The eye is watering and she looks uncomfortable. The other eye appears to be relatively normal by comparison.

Fig. 9.

This is the same girl as in Figure 8 one month after supratarsal subconjunctival triamcinalone under local anaesthetic drops. She is happy and relaxed. The lid swelling has gone. She can now open her eye which is white and quiet. Her left eye which appeared to be relatively normal before, evidently has moderate vernal keratoconjunctivitis too. The lids are a little swollen and the limbal conjunctiva is injected and thickened. She is so pleased with the response in her right eye she is requesting an injection for her left eye.

Fig. 10.

Child with severe limbal VKC. This is a close up of the right eye of the girl in Figure 8. Note the marked conjunctival hyperaemia, Trantas' dots and invasion of cornea by thickened gelatinous pannus.

Fig. 11.

Right eye of child in Figures 8 and 9 one month after supratarsal subconjunctival triamcinalone under local anaesthetic drops. Note that the conjunctiva hyperaemia has gone. The thickened vascularised gelatinous pannus has resolved leaving a mildly pigmented flat scar. The vascular pannus accompanying the pannus has resolved apart from the one larger nasal feeder vessel. Visual acuity had improved from 6/18 to 6/6.

References

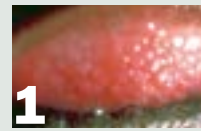- Bonini S, Bonini S, Schiavone M, Centofanti M, et al. Vernal keratoconjunctivitis revisited: a case series of 195 patients with long-term follow-up. *Ophthalmology*. 2000;Jun;107(6):1157-63.
- Bonini S, Coassin M, Aronni S, Lambiase A. Vernal keratoconjunctivitis. *Eye* 2004;18:345-51.
- Cameron JA. Shield ulcers and plaques of the cornea in vernal keratoconjunctivitis. *Ophthalmology*. 1995;102:985-93.
- Saini JS, Gupta A, Pandey SK, Gupta V, Gupta P. Efficacy of supratarsal dexamethasone versus triamcinalone injection in recalcitrant vernal keratoconjunctivitis. *Acta Ophthalmol Scand*. 1999;77:515-8.
- Pucci N, Novembre E, Cianferoni A, et al. Efficacy and safety of cyclosporine eye drops in vernal keratoconjunctivitis. *Annal Allergy Asthma Immunol*. 2002;89:298-303.

Acknowledgments

The authors are grateful to Dr Amos Kibata for helpful comments on a draft of this manuscript. Dr Debbie Carmichael set up the protocols for effective management of VKC at KCMC and prepared a patient information leaflet.

Red Eye Picture Quiz *From page 72*

ANSWERS



1

A 14-year-old boy. Complains of itching eyes for three years with sticky clear discharge. VA 6/6.

Vernal keratoconjunctivitis (Vernal catarrh)

The lumpy appearance of the conjunctiva is caused by swelling of the conjunctiva due to the chronic inflammation. In most cases allergic conjunctivitis will improve in adulthood and does not require intensive treatment. Topical steroids should only be used during acute attacks if there is evidence of corneal damage.

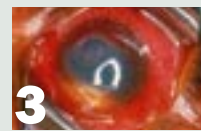


2

45-year-old female. Complains of painful eye and discomfort in bright light with watery discharge. VA 6/12.

Acute anterior uveitis

Photophobia is typical in these patients as the pupil's constriction in the response to light causes pain. The redness is maximum near the limbus (ciliary injection) and the pupil is irregular where it is stuck to the front of the lens. Acute anterior uveitis should be managed with atropine to keep the pupil dilated. Topical steroids may be useful in severe cases.

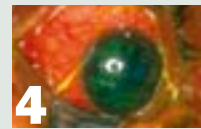

3

Five-year-old girl. Severe pain and loss of vision for three days. Used traditional eye medicines one week ago. VA CF.

Suppurative keratitis

The eye is very red and the iris cannot be seen clearly which suggests the cornea is cloudy. This eye requires hourly topical antibiotics. If facilities are available then a cornea scraping and gram stain should be performed before starting topical treatment. In some regions fungi are a common cause of corneal ulcer and anti-fungal treatment will be required. The white line inferiorly is a hypopyon caused by pus formation in the anterior chamber. It indicates severe inflammation. Traditional eye medicines are not sterile and may cause severe infections.

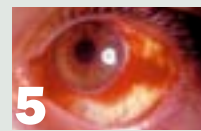

4

Six-year-old male. Painful eye for ten days. Had malaria one month ago. Corneal sensation reduced when tested. VA 6/60.

Herpes simplex keratitis

Not all cases of herpetic simplex keratitis present with a typical dendritic/geographic ulcer. A useful sign of herpes is reduced sensitivity of the cornea. This is thought to be due to damage to the sensory nerves. Herpes keratitis is sometimes associated with febrile illness. Herpes keratitis is managed with a topical antiviral such as acyclovir or trifluorothymidine.

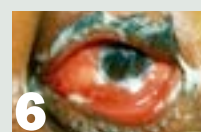

5

25-year-old woman. No pain or discharge complained of red eye since this morning. VA 6/6.

Sub-conjunctival haemorrhage

The lack of pain and discharge imply that there is no inflammation. The very sharply defined edge is typical of a sub-conjunctival haemorrhage. No treatment is required and redness will clear over a course of 2 weeks.



6

19-year-old male. Complains of gritty foreign body sensation, painful eye for three days with sticky yellowish discharge, VA 6/9.

Bacterial conjunctivitis

The entire conjunctiva is red and eye is discharging pus on the lower lid and on the eyelashes. This should be treated with intensive topical antibiotics for one week. In very severe cases, particularly in young men, you should consider doing a gram stain to look for *Gonococcus*, and you should ask specifically about symptoms of urethritis.