

How to manage a patient with glaucoma in Africa



Richard JC Bowman

CBMI Ophthalmologist, CCBRT Disability Hospital, Dar es Salaam, Tanzania. Honorary Senior Lecturer, London School of Hygiene and Tropical Medicine, UK.



Subramaniam Kirupanathan

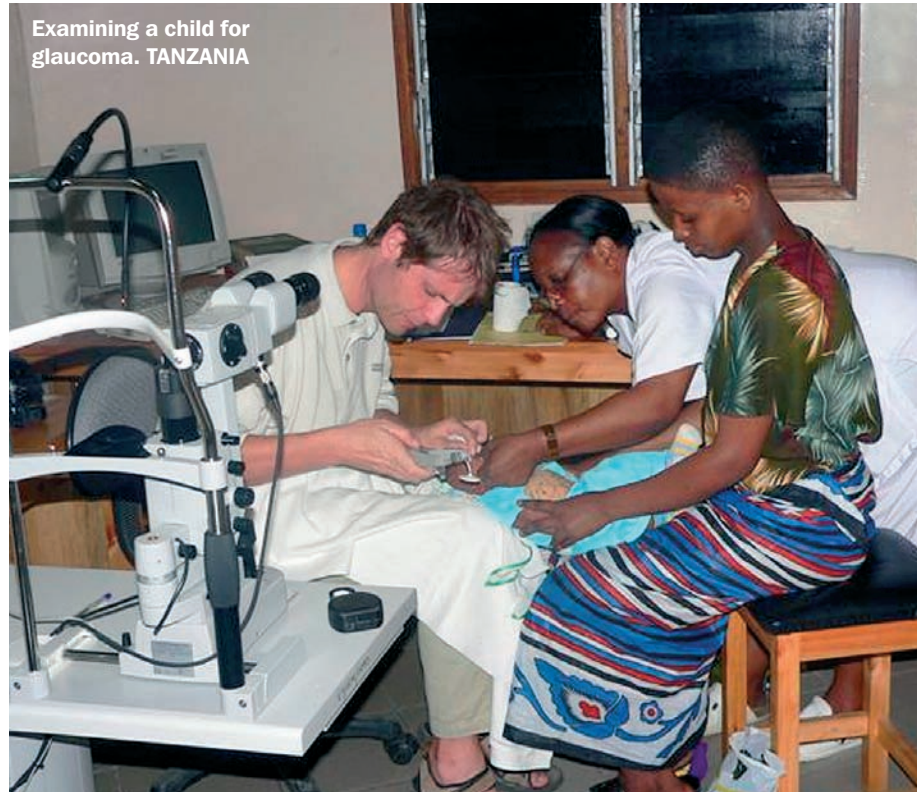
CBMI Medical Advisor for Nigeria and Senior Consultant Ophthalmologist, Medical Director, ECWA Eye Hospital, Kano, Nigeria.

Introduction

How to manage a patient with glaucoma in Africa? The simple answer is: having made the diagnosis by optic disc assessment and intraocular pressure measurements (visual field tests are usually unavailable and unnecessary), perform trabeculectomy surgery using a technique broadly similar to that described by Ian Murdoch in this issue. This article discusses the reasons for this relatively universal management principle. The focus of this article is primary open-angle glaucoma, which affects the large majority of glaucoma patients across the continent. Some brief principles concerning management of other types of glaucoma in Africa are included at the end.

Find the patient

Finding the patient while there is still some useful vision to save is one of the major challenges in the management of glaucoma in Africa. Audits in our hospitals have shown that 29 per cent of glaucoma patients (Dar es Salaam)¹ and 53 per cent of eyes (Kano) present to hospital blind. Seventy per cent of patients had cup/disc ratios of more than 0.8 in their better eye in Dar es Salaam,¹ and 63 per cent of eyes in Kano had cup/disc ratios of more than 0.8. How can we improve on this? Population-based glaucoma screening is not advocated because there is no good screening test and it is impractical. However, there are many active community outreach programmes targeting those with treatable blindness and visual impairment, such as cataract, which can also be used to refer glaucoma patients earlier than they might present themselves to hospital. Outreach workers can be trained in intraocular pressure (IOP) measurement and disc assessment. However, neither are very specific or sensitive screening tests and, as hospitals are able to offer more comprehensive eye care services, even the field assessment of discs and the measuring of IOP may not be necessary. Reduced visual acuity could be used instead. For example, if spectacles can be provided for refractive errors and high-quality cataract surgery for immature cataracts, then all patients with visual acuities less than 6/18 could be referred back to the hospital. Full assessment would then pick up some glaucoma patients earlier than many are currently presenting. Although visual acuity is not thought of as a screening test for



Richard Bowman

‘Surgery is almost always the correct treatment in Africa, where medical therapy throughout the patient’s lifespan is impractical’

glaucoma, it may be the most practical for Africa, where advanced disease does affect visual acuity.

Address barriers to acceptance of surgery

A number of studies have demonstrated poor uptake of glaucoma surgery in Africa even when it has been provided free.^{1,2} This is not surprising. The operation compares poorly with cataract surgery in terms of patient perception; the best that the patient can hope for is retention of current level of vision, and there is indeed a moderate risk of visual deterioration, both acutely (usually transient) and chronically, due to cataract.^{2,4} An audit at our hospital (CCBRT Disability Hospital, Dar es Salaam) revealed that some of the barriers to surgery may be related to gender; women were not only less likely to present to the hospital with glaucoma, but also less likely to be referred for surgery once they do present. This requires further investigation.

How can we overcome these barriers?

- 1 Careful counselling about the reason for surgery, expected outcomes, and the high risk of blindness without surgery. This should be provided preferably by trained full-time counsellors.
- 2 Programmes with cost-recovery schemes may need to consider charging less for trabeculectomy than for cataract surgery. We currently charge the same for both, but maybe it is unrealistic to expect patients to pay the same fee for an operation offering no chance of better vision as for one offering a high chance of better vision. However, user fees are certainly not the only barrier, since there has been poor uptake of free surgery in Tanzania, as explained above.
- 3 Pay careful attention to surgical technique to maximise chances of successfully lowering pressure and to minimise the risk of subsequent visual loss (see next section and Ian Murdoch’s article).

- 4 There may be a case for more widespread use of combined cataract and glaucoma surgery in Africa, for patients with glaucoma and immature cataract. This would increase the benefit to the patient (possible improved post-operative visual acuity and less risk of post-operative visual deterioration due to cataract). However, this is more difficult surgery than either cataract or trabeculectomy alone, and is known to have a higher drainage failure rate than trabeculectomy alone. Furthermore, it has not been reported systematically in Africa.

Perform the surgery

Surgery should select techniques based on the assumption that you may not see the patient again after discharge. Surgery is almost always the correct treatment in Africa, where medical therapy throughout the patient's lifespan is impractical. Two studies of patients presenting to hospital with glaucoma have demonstrated that previous drainage surgery is associated with better vision¹ and lower IOPs^{1,3} than previous medical therapy.

We advocate techniques similar or identical to those described by Ian Murdoch in this issue, with emphasis on achieving a diffuse posterior bleb and avoiding a post-operative hypotony or anterior chamber shallowing, which have been shown to increase the risk of subsequent visual loss.⁴

Use of anti-scarring treatments in Africa

Patients of African origin are known to be at higher risk of failure of trabeculectomy surgery because of subconjunctival scarring. This has led to widespread use of anti-scarring adjunctive therapy given at time of surgery. Although good results have been described in African and Afro-American patients without these agents, comparative studies tend to suggest a benefit from their use. Mitomycin C (MMC) may result in lower pressures than 5 fluorouracil (5FU), but may also be accompanied by high rates of complications.⁵⁻⁸ This, together with its higher toxicity and price, and lower pharmacological stability compared to 5FU, have led some to question the suitability of MMC for widespread use in Africa. In conclusion, if anti-scarring agents are available, use them but remember that they will exaggerate the consequences of any error in surgical technique (especially MMC). Extra effort must be made to ensure that the scleral flap and conjunctival flap (especially anteriorly) are securely sutured, and to apply the anti-scarring agent over a wide surface area, in order to try to achieve a diffuse posterior bleb rather than an anterior cystic one.

Manage post-operative complications

Acute complications

Shallow AC

This may be due to leakage of aqueous under the conjunctival flap (Seidel positive), in which case resuturing of the conjunctiva is required. It may also be due to excessive drainage through the fistula (large bleb, Seidel negative). In the latter case, conservative measures may be tried initially (atropine, pad and bandage, short course of diamox), but it may be necessary to resuture the scleral flap if these fail. Both the above causes of shallow AC are associated with hypotony, but if the IOP is high with a shallow AC, then aqueous misdirection syndrome must be considered. Try atropine drops and diamox. If this fails, lens removal and anterior vitrectomy may be necessary.

High IOP

Cut or release (if releasable) posterior scleral sutures and massage behind the posterior edge of the scleral flap to encourage posterior drainage. If this fails, the sclerostomy may be blocked and should be explored and revised if necessary.

Chronic complications

Failure of IOP control

This is usually due to scarring down of the scleral flap and conjunctiva, and the bleb often looks flat. Needle revision of the bleb can be tried. We do this in theatre in the following way: use a micro vitreal blade (MVR blade) to enter the subconjunctival space above the bleb; advance it subconjunctivally into the area of the bleb to dissect any scarring, then penetrate beneath the scleral flap into the AC, and lift the flap as it is withdrawn (the bleb usually appears instantly). Subconjunctival 5FU is then injected above the bleb. If one or two needle revisions fail, repeat trabeculectomy can be performed; this is usually easier to do in a new site if there is room. Repeat trabeculectomy carries a high risk of scarring and failure, and MMC should be used if available.

Cataract

This should be removed using a section placed away from the bleb (i.e. corneal or temporal limbal).

Make every effort to achieve follow-up

A number of studies from Africa report poor long-term follow-up.^{4,8} This is one of the reasons why surgical technique has to be even more accurate than in industrialised countries, where good follow-up is the norm (only 7 per cent of patients at Kano had more than two weeks' follow-up). It is important to try to improve this, since late failure of drainage or treatable visual loss from cataract may occur. Counselling about the importance of follow-up is essential and financial incentives such as partial reimbursement of surgical fees or transport costs may be appropriate.

Other types of glaucoma

Normal tension glaucoma (NTG)

The difficulty in Africa is being sure of the diagnosis in the absence of progressive visual field changes. Patients with glaucomatous discs, history of progressive visual deterioration and normal IOPs should usually undergo trabeculectomy which has been shown to be of benefit for NTG.

Angle-closure glaucoma

Uncommon in Africa, except in Asian populations, and therefore commonly missed.

Primary congenital glaucoma

The choice is between goniotomy, trabeculectomy and trabeculectomy, preferably by a sub-specialist.

Rubeotic glaucoma

The eye is usually blind from retinovasculature disease and the emphasis should be on keeping the patient comfortable (topical steroids, atropine and cyclophotocoagulation, retrobulbar alcohol or enucleation if necessary).

References

- 1 Mafwiri M, Bowman RJ, Wood M, Kabiru J. Primary open-angle glaucoma presentation at a tertiary unit in Africa: intraocular pressure levels and visual status. *Ophthalmic Epidemiol* 2005 Oct;12(5): 299-302.
- 2 Quigley HA, Buhrmann RR, West SK, Isseme I, Scudder M, Oliva MS. Long-term results of glaucoma surgery among participants in an east African population survey. *Br J Ophthalmol* 2000;84: 860-864.
- 3 Verrey JD, Foster A, Wormald R, Akumoa C. Chronic glaucoma in northern Ghana – a retrospective study of 397 patients. *Eye* 1990;4: 115-20.
- 4 Kabiru J, Bowman R, Wood M, Mafwiri M. Audit of trabeculectomy at a tertiary referral hospital in East Africa. *J Glaucoma* 2005 Dec;14(6): 432-434.
- 5 Mermoud A, Salmon JF, Murray AD. Trabeculectomy with mitomycin C for refractory glaucoma in blacks. *Am J Ophthalmol* 1993;116: 72-78.
- 6 Singh K et al. Trabeculectomy with intra-operative 5-fluorouracil vs mitomycin C. *Am J Ophthalmol* 1997;123: 48-53.
- 7 Mwanza JC, Kabasele PM. Trabeculectomy with and without mitomycin-C in a black African population. *Eur J Ophthalmol* 2001 Jul-Sep;11(3): 261-3.
- 8 Yorston D, Khaw PT. A randomised trial of the effect of intraoperative 5-FU on the outcome of trabeculectomy in East Africa. *Br J Ophthalmol* 2001;85: 1028-1030.