

## What's new at the back of the eye?

### EDITORIAL



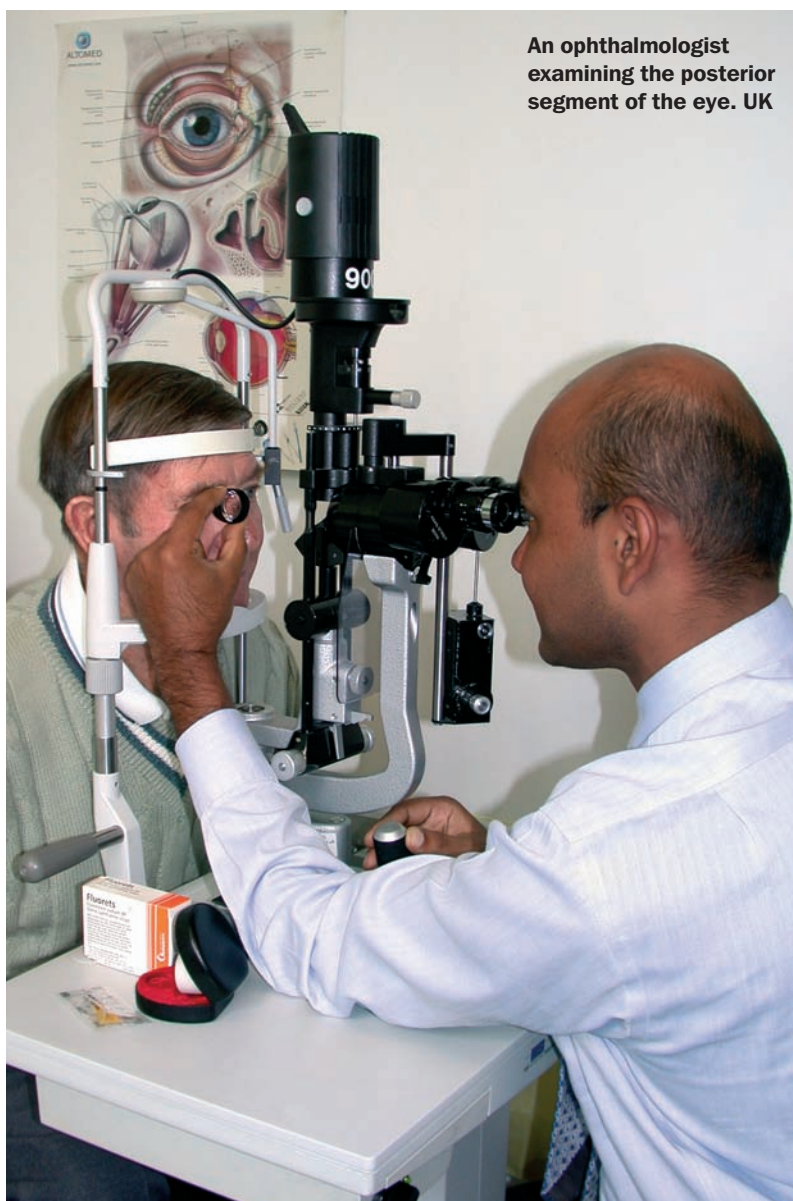#### Ivo Kocur

VISION 2020 Global Coordinator, World Health Organization, Prevention of Blindness and Deafness, Chronic Diseases and Health Promotion, CH-1211, Geneva 27, Switzerland.

### The changing demographic pattern of visual impairment

VISION 2020 and the prevention of visual impairment are moving into the political and public spotlight. Recent WHO discussions on the growing incidence of chronic, age-related, non-communicable diseases indicate that visual health and its preservation are now receiving attention. Recent publications illustrate the changing demographic pattern of visual impairment, implications for public health and possible interventions to control sight-threatening conditions. Both *The State of the World's Sight*, *VISION 2020: the Right to Sight, 1999-2005*,<sup>1</sup> published jointly by WHO and the International Agency for the Prevention of Blindness (IAPB), and an article in the *World Health Bulletin*, November 2004,<sup>2</sup> illustrate these trends. The recent WHO data on blindness give clear evidence: among the causes of blindness, the share of chronic, age-related, non-communicable potentially blinding eye conditions is dramatically increasing (Figure 1, over page). *The State of the World's Sight* provides an insight into what has thus far been achieved in the prevention of visual impairment through international alliances and collaboration since the launch of VISION 2020 in 1999. Attempts to modernise the attitude of health care providers towards the preservation of visual health have been further cultivated by the representatives of many WHO member states when adopting, in 2003, the Resolution on the Elimination of Avoidable Blindness, and when preparing a new resolution for the World Health Assembly in 2006. What does all this mean for eye health care professionals – new challenges, new opportunities?

*Editorial continues over page* ►



An ophthalmologist examining the posterior segment of the eye. UK

Richard Leung

### IN THIS ISSUE...

#### EDITORIAL

- 1 **What's new at the back of the eye?**  
Ivo Kocur

#### ARTICLES

- 4 **What's new in age-related macular degeneration?**  
David Yorston
- 6 **Can we grow new retina?**  
Geeta K Vemuganti

#### REPORT

- 8 **What will be new at the back of the eye in the year 2020?**  
Shaheen Shah reports from the World Ophthalmology Congress, including a glossary

#### EVIDENCE-BASED EYE CARE

- 11 **Cochrane Eyes and Vision Group (CEVG) systematic review activity on back of the eye treatments**  
Cochrane Eyes and Vision Group

#### HOW TO...

- 12 **How to prescribe spectacles for presbyopia**  
R n e du Toit

#### 13 EXCHANGE

Including an inexpensive tool for examining the fundus, using eye shields, a free histopathology service and a KAP study from South India

#### 15 NEWS AND NOTICES

Including findings from the Reader Survey



The journal is produced in collaboration with the World Health Organization



Volume 19 | Issue No. 57 | March 2006

## Editor

Victoria Francis

## Editorial Committee

Professor Allen Foster  
Dr Clare Gilbert  
Dr Murray McGavin  
Dr Ian Murdoch  
Dr GVS Murthy  
Dr Daksha Patel  
Dr Richard Wormald  
Dr David Yorston

## Regional Consultants

Dr Grace Fobi (Cameroon)  
Professor Gordon Johnson (UK)  
Dr Susan Lewallen (Tanzania)  
Dr Wanjiku Mathenge (Kenya)  
Dr Babar Qureshi (Pakistan)  
Dr Yuliya Semenova (Kazakhstan)  
Dr B R Shamanna (India)  
Professor Hugh Taylor (Australia)  
Dr Andrea Zin (Brazil)

## Advisors

Dr Liz Barnett (Teaching and Learning)  
Catherine Cross (Infrastructure and Technology)  
Sue Stevens (Ophthalmic Nursing and Teaching Resources)

## Administration

Ann Naughton (Administrative Director)  
Anita Shah (Editorial/Administrative Assistant)

## Editorial Office

Community Eye Health Journal  
International Centre for Eye Health  
London School of Hygiene and Tropical Medicine,  
Keppel Street, London WC1E 7HT, UK.

Tel: +44 207 612 7964/72

Fax: +44 207 958 8317

Email: Anita.Shah@Lshhtm.ac.uk

## Information Service

Sue Stevens

Email: Sue.Stevens@Lshhtm.ac.uk

Tel: +44 207 958 8168

## On-line Edition ([www.jceh.co.uk](http://www.jceh.co.uk))

Sally Parsley

Email: admin@jceh.co.uk

Community Eye Health Journal is published four times a year and **sent free to developing country applicants**. French, Chinese and Indian editions are also available. Please send details of your name, occupation and postal address to Community Eye Health Journal, at the address above. Subscription rates for applicants elsewhere: one year UK£28/US\$45; two years UK£50/US\$80. Send credit card details or an international cheque/banker's order made payable to London School of Hygiene and Tropical Medicine to the address above.

## Website

Back issues are available at

[www.jceh.co.uk](http://www.jceh.co.uk)

Content can be downloaded in both HTML and PDF formats.

© International Centre for Eye Health, London

Articles may be photocopied, reproduced or translated provided these are not used for commercial or personal profit. Acknowledgements should be made to the author(s) and to Community Eye Health Journal. All graphics by Victoria Francis unless stated otherwise.

ISSN 0953-6833

The journal is produced in collaboration with the World Health Organization. Signed articles are the responsibility of the named authors alone and do not necessarily reflect the policies of the World Health Organization. The World Health Organization does not warrant that the information contained in this publication is complete and correct and shall not be liable for any damages incurred as a result of its use. The mention of specific companies or of certain manufacturers' products does not imply that they are endorsed or recommended by the World Health Organization in preference to others of a similar nature that are not mentioned.

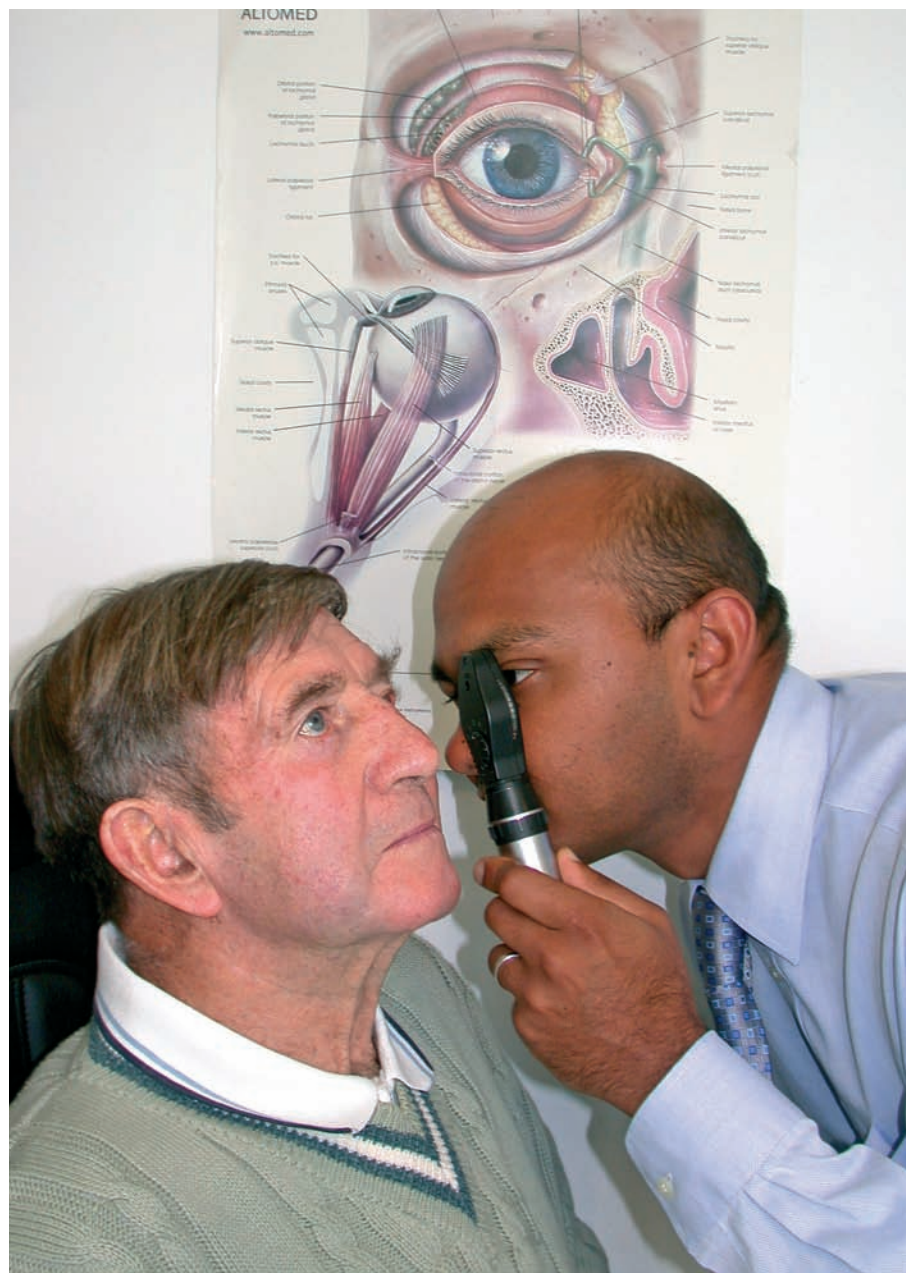
## Meeting the challenge through specialised eye care services

One challenging aspect of the latest WHO data on the changing pattern of blindness prevalence in the world is that the demand for high-quality eye care services is expected to increase. Predicted population growth, along with the increase in life expectancy, will substantially alter the picture of future recipients of eye care. The numbers of people affected by sight-threatening eye conditions requiring highly specialised health services are likely to increase.

One such condition is diabetes. Diabetic retinopathy accounts for about 5 per cent of the global pattern of blindness. WHO is expecting a significant increase in the incidence of diabetes in all geographic regions. For instance, in many highly populated countries in Asia, the number of individuals suffering from diabetes will double by 2030.

Glaucoma is another example which, from the public health perspective, may be even more challenging. Controlling blindness from glaucoma requires early detection, life-long treatment and the compliance of patients. It is estimated that glaucoma is responsible for 12 per cent of global blindness. However, numerous unresolved issues in glaucoma control deprive many populations from effectively planned and delivered specialised eye care services.

The WHO data also indicate the growing threat of age-related macular degeneration. The increasing share of this eye condition is progressively reshaping the ratio of avoidable sight-threatening eye conditions to those in which conventional eye care is thus far failing. Cataract is another age-related eye condition causing avoidable blindness. Given that it has been one of the major stimuli for technological research and development in eye care, the failure of modern society to adequately control



Richard Leung

Direct ophthalmoscopy provides a magnified view of the fundus.UK

# 'The recent WHO data on blindness give clear evidence: among the causes of blindness, the share of chronic, age-related, non-communicable potentially blinding eye conditions is dramatically increasing.'

cataract blindness is particularly shameful. The last WHO data indicate that cataract is still responsible for almost half of global blindness. Its cure is known, and several options for its surgical treatment have been tested and broadly implemented to reasonably fit healthcare budgets, even in the poorest societies. Demographic changes and longevity, along with the lack, for the foreseeable future, of knowledge about cataract prevention, will further increase the demand for cataract surgical services. Age-related macular degeneration poses a different set of challenges, as the condition cannot be prevented, and only some forms are amenable to very expensive, time-consuming interventions which are of limited benefit. The mainstay will need to be rapid expansion of low vision services, along with raising awareness among the general public and eye care professionals.

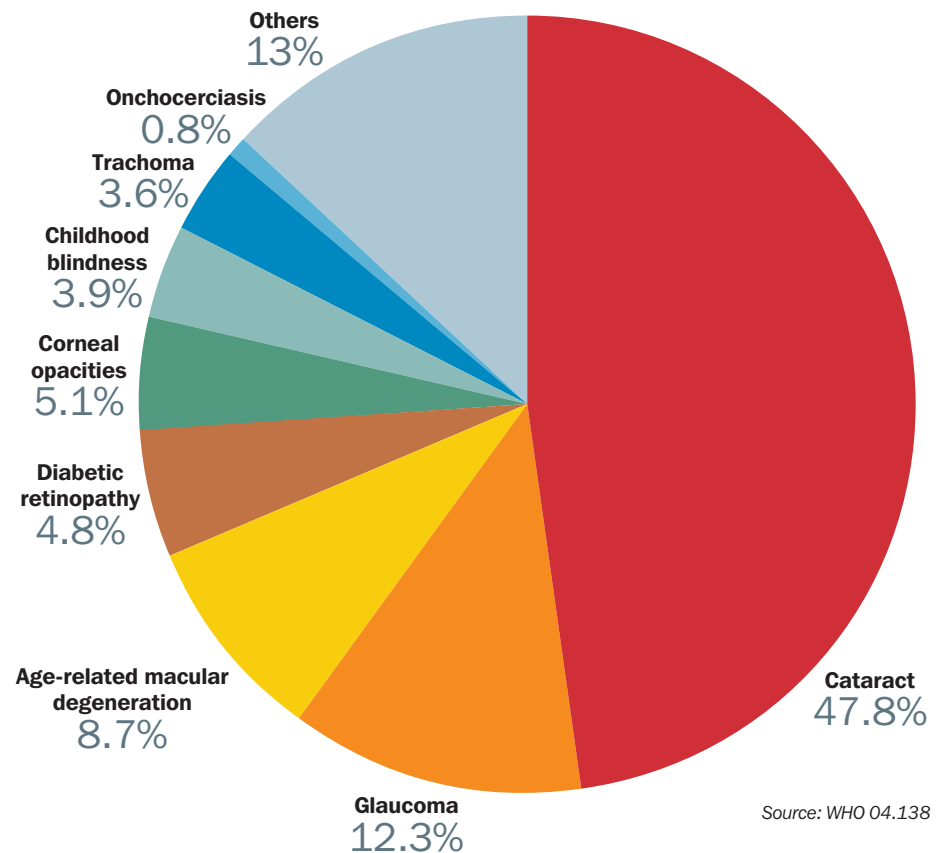
The implications of demographic changes and the ageing of populations are a growing concern. However, preventable and treatable sight-threatening eye conditions occurring in children must also remain among the top priorities. The World Health Bulletin of November 2004<sup>2</sup> also sent a strong warning signal emphasising the need to address uncorrected refractive errors, an often overlooked public health issue relevant to all age groups. The importance of refractive errors in the pattern of visual impairment is likely to be substantially greater than generally assumed.

## The need for targeted action and an interdisciplinary approach

The current situation presents us with a new opportunity for targeted action. The preservation of visual health requires, more than ever, a coordinated approach by health care providers, who will develop comprehensive, integrated eye care services. An effectively designed eye care component in primary, secondary and tertiary health care is an essential prerequisite to respond adequately to the changing pattern of avoidable visual impairment. Over the long term, vertical interventions and projects oriented to a single eye disease may no longer bring the desired achievements.

The nature of the causes of blindness which WHO considers to be preventable and/or treatable, and therefore avoidable, requires an interdisciplinary approach for long-term control. For example, controlling diabetic retinopathy is complex, requiring: health education to prevent diabetes; early diagnosis of diabetes; comprehensive, cost-

Figure 1: Global causes of blindness as a percentage of total blindness in 2002



Source: WHO 04.138

effective screening programmes to detect diabetics with treatable retinopathy; laser treatment and follow-up; and patient education and compliance. In many countries, attitudes about diabetes control are being reshaped by constituting national diabetes control programmes, rather than by pursuing the control of this disease through uncoordinated efforts within individual medical sub-specialties. In those countries where the number of diabetic patients is rapidly increasing, introducing control programmes on the scale needed will be extremely challenging. We need to educate more ophthalmologists to manage diabetic retinopathy, make appropriate technology available, develop new programmes, establish new partnerships, and develop a major public health education strategy.

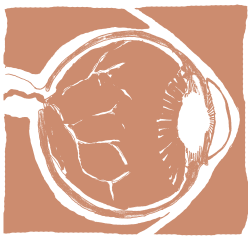## Integrating eye care into national health plans

Health care providers in the most affluent societies and in many other countries with modern health care systems are becoming increasingly interested in comprehensive, integrated care. In this context, eye care providers have three responsibilities: to be ready to explain the known and tested options in blindness control to national

health care planners and providers; to be proactive in health care policy development; and to take part in updating national health care strategies where eye care should be addressed. It would be disappointing to lose the opportunity for integrating eye care into national health care plans because of a failure to provide health care planners with an adequate briefing on the management of sight-threatening conditions. Several national health care areas should be explored, especially neonatal care, health care programmes for mothers and children, preventive health care programmes for working-age populations as well as for the elderly. As the world copes more adequately with the challenges of blindness control, eye care professionals will play a vital role in advocating for comprehensive health care which integrates and adequately addresses visual health.

### References

- 1 World Health Organization and International Agency for the Prevention of Blindness. The state of the world's sight. VISION 2020: The Right to Sight 1999 - 2005. Geneva: WHO, 2005.
- 2 Resnikoff S, Pascolini D, Etya'ale D, Kocur I, Pararajasegaram R, Pokharel G, Mariotti S. Global data on visual impairment in the year 2002. Bulletin of the World Health Organization 2004; 82: 844-85. [www.who.int/bulletin/volumes/82/11/en/844.pdf](http://www.who.int/bulletin/volumes/82/11/en/844.pdf)



# What's new in age-related macular degeneration?



**David Yorston**

Consultant Ophthalmologist, Tennent Institute of Ophthalmology, Gartnavel Hospital, 1053 Great Western Road, Glasgow G12 0YN, Scotland.

## Introduction

Age-related macular degeneration (AMD) was regarded as unimportant in global blindness, of relevance only to the minority of the world's population that live in wealthy countries. However, increasing life expectancy, particularly in Asia, has challenged this view. The latest WHO estimates of global blindness suggest that there are over 3 million people blinded by AMD, representing 9 per cent of global blindness. Only cataract and glaucoma cause more blindness.

## What is AMD?

AMD is a disorder affecting people over the age of 55. It affects the macula in the centre of the retina. The macula is essential for detailed fine vision tasks, such as reading and recognising faces. There are two types of AMD, dry and wet. Dry macular degeneration is often asymptomatic. However, patients may progress to vision loss through progressive atrophy of the macular tissue (an advanced dry form termed geographic atrophy). Wet, or exudative, AMD is characterised by a more rapid change in vision due to haemorrhage and fluid leakage (see Figures 1a & 1b).

## Clinical features

Wet AMD is due to a fibrovascular membrane growing under the retina. These abnormal choroidal new vessels (CNV) arise in the choriocapillaris, therefore, unlike retinal vessels, they leak fluid. This causes a localised retinal detachment at the fovea (central macula), which may be surrounded by oedema and exudates. In addition, the blood vessels may rupture causing sub-retinal haemorrhage (see Figure 2). Eventually, the membrane becomes inactive leaving a white fibrous scar under the macula. At this stage

the vision is usually reduced to Counting Fingers (CF) or Hand Movements (HM).

The earliest symptom of AMD is distortion of straight lines. Doorways or window frames may appear bent or twisted – a symptom known as metamorphopsia. This is caused by the small blister of fluid under the fovea. Later, the patient will complain of loss of central vision, and the visual acuity will be reduced. Unlike in cataract or glaucoma, only the central vision is affected, so most patients are able to navigate unaided. On examination, it is often possible to see the elevated fovea, and there may be sub-retinal haemorrhage and hard exudates as well. These are much easier to detect using a biomicroscopic lens, such as a 78 or 66 dioptre lens. This gives a stereoscopic view of the macula, which is not possible with a direct ophthalmoscope.

The definitive investigation is fluorescein angiography. Fluorescein dye is injected intravenously, and as it circulates around the eye, a series of photographs are taken of the retina using a blue light to illuminate the retina. The fluorescein then emits green light, which is detected by the camera. Unlike normal retinal blood vessels, the CNV leak fluorescein, and this can be seen as a bright area in the angiogram photos (see Figure 3). The fibrovascular membranes are classified as either 'classic' (well-defined on fluorescein angiography), or 'occult', if leakage is seen but the membrane is not well-defined. New digital fundus cameras, which are expensive to buy but have very low running costs, are making fluorescein angiography more accessible.

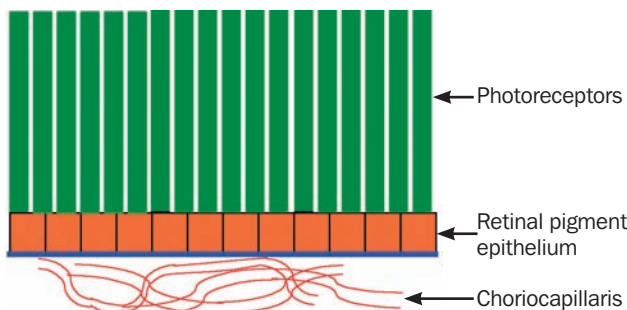
Dry AMD causes a very gradual loss of vision, and is visible as an area of atrophy of the retinal pigment epithelium under the fovea.

## Risk factors

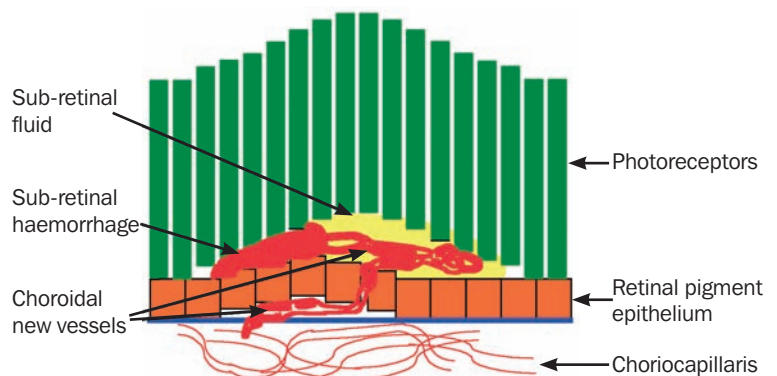
No one knows exactly what causes AMD, but there have been some important developments recently. Firstly, we know that age is the most important risk factor. The condition is much more common in people aged 80 or over. Unfortunately, we cannot modify this risk factor as we are all ageing. Several epidemiological surveys have demonstrated that smoking is a risk factor for AMD. The link between smoking and blindness is now well known, and this is an important public health message. Smoking one pack of cigarettes per day for 40 years is associated with a threefold increase in the risk of AMD. Even passive smoking is associated with an increased risk, but stopping smoking appears to reduce the danger. Possibly 15 per cent of AMD cases are caused by smoking. Genetic influences are also important. Several recent studies have shown that a variant of the gene that encodes complement factor H (a protein that helps to regulate the body's response to inflammation) and a second gene, less characterised and located on chromosome 10, are independently associated with AMD. As many as 40-50 per cent of all cases of AMD may be caused by these gene variations.

## Prevention

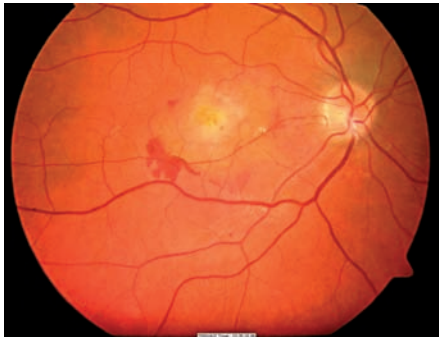There is no perfect method of preventing AMD. Stopping smoking reduces the risk, but does not abolish it entirely. A large study in the USA showed that taking high doses of vitamins A, C, and E, combined with zinc supplements, significantly reduced the risk of progression in AMD. The treatment was protective against CNV, but had no clear effect on geographic atrophy. The supplements are most beneficial when used in patients at greater risk of developing wet



**Figure 1a. Normal fovea, showing relationship of photoreceptors, retinal pigment epithelium and choriocapillaris**



**Figure 1b. In neovascular AMD, blood vessels grow from the choriocapillaris under the retina, causing serous detachment of the pigment epithelium and the retina. Ultimately the vessels are replaced by a dense fibrous scar, leading to loss of the photoreceptors**



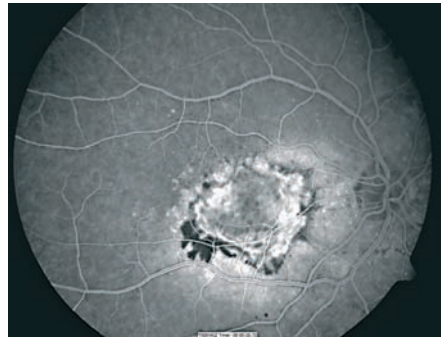
**Figure 2.** This colour slide shows a choroidal neovascular membrane under the fovea. There is a sub-retinal haemorrhage infero-temporally, and the grey membrane can also be seen under the retina, next to the blood

AMD, particularly patients who already have one eye affected by wet AMD. In these patients, the supplements reduce the risk of developing wet AMD in the second eye by about 25 per cent. Smokers should not use this treatment, as it may increase their risk of lung cancer. It is estimated that in the USA there are 8 million people over 55 who are at risk and that 1.3 million of them are likely to lose vision as a result of AMD over the next five years. Use of vitamin and zinc supplements would reduce this by 300,000, and stopping smoking might reduce it even further. We should ensure that patients at risk have access to vitamin supplements, and should take every opportunity to stress the strong link between smoking and blindness.

## Treatment

No treatment has been shown to be effective against geographic atrophy. For many years the only treatment for CNV was laser photocoagulation. This is effective, but, as the treatment destroys the overlying retina, it also results in irreversible loss of central vision; therefore laser photocoagulation is only useful in the 10 per cent of patients with wet AMD in whom the CNV are located away from the fovea.

Recently some vision-sparing treatments have become available. The first of these is photodynamic therapy (PDT) with verteporfin. Verteporfin is a drug that only becomes active when exposed to light of a particular wavelength. It is injected intravenously, and then the area of choroidal new vessels is irradiated with a low-powered laser that emits light at the correct wavelength. This activates the verteporfin, and it destroys the abnormal blood vessels under the fovea, without damaging the overlying retina. The results of clinical trials show that the risk of visual loss is halved in patients with a classic (well-defined on fluorescein angiography) membrane. About 60 per cent of the treated patients lost less than three lines of vision after two years, compared to 30 per cent of the patients given a placebo. Unfortunately, verteporfin is very expensive, and treatment often has to be repeated. Even in wealthy countries there has been intense debate about whether this



**Figure 3.** The fluorescein angiogram of the same eye shows the membrane much more clearly. The black area corresponds to the haemorrhage, and the membrane is seen as a bright irregularly shaped area of approximately two disc diameters' width

is affordable and cost-effective.

All new vessels in the eye, whether retinal or choroidal, grow in response to angiogenic factors – chemicals that promote the growth of new blood vessels. One of the most important is Vascular Endothelial Growth Factor (VEGF). A number of different drugs are effective at blocking the action of VEGF. Unfortunately, because VEGF is useful in other parts of the body, these drugs blocking it cannot be administered systemically and must be delivered directly to the retina. This usually means repeated intraocular injections.

The first of these drugs is pegaptanib. A randomised trial comparing intra-vitreous injections of pegaptanib every six weeks with sham injections showed that, after one year, 70 per cent of the treated patients lost less than three lines of vision compared to 55 per cent of controls. The effectiveness of this treatment was not influenced by the type of choroidal new vessel membrane – it worked equally well in occult and classic membranes. Unfortunately, 1.3 per cent of patients given the injections developed endophthalmitis, and 0.6 per cent had a retinal detachment. It is not known for how long the treatment must be continued, but it seems probable that stopping the injections would lead to reactivation of the new vessels. A second drug that is not yet available, called ranibizumab, also works by blocking the action of VEGF. It has shown even more promising results, with less than 10 per cent of patients losing three lines of vision and over 30 per cent gaining at least two lines.

Anecortave is an angiostatic steroid which means it does not possess any glucocorticoid action and has none of the usual ocular side-effects of steroids, such as elevated IOP or reduced immunity. It is being evaluated both for the treatment and prevention of wet AMD. Anecortave can be given by sub-Tenon's injection and a treatment may be effective for six months. A recent clinical trial compared sub-Tenon's injection of anecortave to PDT with verteporfin. In both treatment groups, about 45 per cent of patients lost less than three lines of vision. The injections must be repeated every six months, but appear to be very safe. Because PDT was used in the control group,

all patients had classic membranes, so there is no information on the effectiveness of anecortave in occult membranes. We are awaiting results from more clinical trials.

Although PDT, pegaptanib and anecortave are all effective at reducing the rate of visual loss, they are not a complete cure. They significantly reduce the risk of blindness, but do not restore normal vision. In most trials, success was defined as loss of less than three lines of vision, so an eye that dropped from 6/36 to 6/60 after treatment would be regarded as a success, although the patient would still have poor vision.

The alternative to medical treatment is surgery. Although no large trials have been carried out, retinal translocation appears to offer some hope to patients who develop CNV in their second eye. The principle of this operation is that the CNV are a response to abnormalities in the retinal pigment epithelium and choroid, but the overlying macula is initially healthy. If the macula could be moved to another part of the retina, with healthy pigment epithelium, it would regain its function. This is achieved by a pars plana vitrectomy, after which the retina is then completely detached by injecting saline under the retina through a 40 gauge needle. Once the retina is detached, a 360 degree retinotomy is carried out just behind the ora serrata. The CNV membrane can then be picked up and removed with fine intraocular forceps. The retina is only attached at the optic disc, and it can be rotated by about 45 degrees, so that the macula now lies over healthy choroid. The retina is re-attached by filling the vitreous cavity with silicone oil. After three months, the silicone oil is removed and the superior and inferior oblique muscles are adjusted so that the eyeball is rotated in the opposite direction and the macula is once again at the centre of the visual axis. This is very complex and costly surgery. However, in the largest series to date, the median distance visual acuity improved from 6/36 to 6/24, and reading vision improved even more, with the median reading speed increasing from 71 to 105 words per minute.

Despite our best efforts, many patients will be left with profound visual loss. Although this may not be curable, we can still help by providing low vision aids, and social support. Peripheral navigational vision is usually preserved, so mobility training is not usually required. However, poor reading vision may be very disabling, and although magnifying low vision aids are unlikely to improve vision enough to read a book, they allow the patient to read prices in the market or headlines in a newspaper.

## Conclusion

As the world's population ages, we will face an increasing challenge from AMD. Although there have been some very significant advances in our understanding of the causes and treatment of AMD, we are still a very long way short of a cure or an effective prevention.



# Can we grow new retina?



**Geeta K Vemuganti**

Director, Ophthalmic Pathology Service, Head, Sudhakar and Sreekant Ravi Stem Cell Laboratory, L.V. Prasad Eye Institute, L.V. Prasad Marg, Banjara Hills, Hyderabad - 500 034, India.  
Email: geeta@lpei.org

## Introduction

Retinal degenerations and dystrophies, the major causes of genetically inherited blindness, are characterised by the death or degeneration of photoreceptors (rods and/or cones).<sup>1</sup> Approaches to treating this disease include: a) replacing the defective gene; b) introducing a drug or agent that either slows down or stops the premature death of photoreceptors; c) introducing electronic chips; or d) replacing the damaged cells by cellular therapy. Gene therapy is aimed at counteracting the defective gene by substituting it with the normal gene in the target tissues. Though successful visual recovery has been reported with gene therapy in dog models,<sup>2-3</sup> it remains a challenge to identify a safe and reliable way of introducing the corrective gene in humans, given that the genes need to act for the lifetime of the patient. Introduction of 'a' factors (such as growth factors) into the eye, directly or through implants, is another novel approach to preventing or slowing premature cell death.<sup>4-5</sup> The challenge lies in delivering the drug to the appropriate site in a safe and sustained manner. Electronic chips, similar to the ones used for audio aids, have shown exciting results in some studies, but the technology is still in its infancy.<sup>6-7</sup>

As knowledge relating to stem cells has increased over the last two decades, attempts have been made to translate this research into clinical practice, particularly for ocular surface reconstruction. Certain ocular surface disorders, like chemical burns, cause damage to the corneal epithelial stem cells. The consequence of this is that the normal corneal epithelium is replaced by conjunctival epithelium, which leads to corneal opacity and vascularisation, with loss of vision. Many centres across the world,<sup>8-10</sup> including our centre,<sup>11-13</sup> have grown sheets of epithelial cells from stem cells, supported on amniotic membrane. These sheets of cells have then been successfully transplanted to cover the entire corneal surface in individuals with ocular surface disorders, leading to less inflammation and scarring. Though the clinical outcome of this new technique is well established, there are still many unanswered questions, particularly in relation to the long-term survival of the transplanted cells.

## What are stem cells?

Stem cells are defined as undifferentiated ('primitive') cells that are capable of self-renewal (dividing) and differentiation (changing into cells which have different structural characteristics and function). There are basically two types of stem cells,

embryonic and adult stem cells. The embryonic cells are totipotent and pluripotent, with a potential to generate all the types of cells. The adult stem cells are few in number and are located in different parts of the body, like bone marrow, skin, and intestinal mucosa, and serve the purpose of regenerating that particular tissue/cells of the body throughout the life span. It is now known that some of these adult stem cells, in addition to generating cells of their own lineage, can also generate cells of other lineages by a principle called 'transdifferentiation' or 'plasticity'.<sup>14</sup> Bone marrow stromal cells, also called mesenchymal stem cells, are the best example of such cells, as they have the potential to form bone, cartilage, neurons and muscle cells.

## What is cell therapy?

Conceptually, cell therapy can be broadly classified into four types:

- (a) autologous and homogeneous – i.e. the use of the patient's own adult stem cells to regenerate cells of the same kind, e.g. skin cells, limbal stem cells;
- (b) autologous and non homogeneous – i.e. the use of the patient's own cells, but to make cells of a different kind, for example regeneration and remodelling of myocardium after injecting autologous bone marrow-derived stem cells;
- (c) allogenic cell therapy – i.e. the use of cells of the same kind, but from a different donor. This requires the use of immunosuppressive drugs to prevent the rejection of cells, e.g. bone marrow transplantation;
- (d) embryonic cell therapy – i.e. the use of embryonic cells that have been characterised, isolated and shown to differentiate along the desired cell type only.

This article presents a conceptual approach to cell therapy and a brief review of progress in this field.

## Which cells to choose?

Referring to the above classification of cell therapy, in principle, retina could be grown from: a) stem cells within the retina, retinal stem cells (Figure 1); b) stem cells within the eye, but outside the retina, e.g. ciliary body stem cells or retinal pigment epithelial cells; c) from the patient's own tissues, but using non-ocular sources, e.g. bone marrow stromal cells or neural stem cells; d) non-self stem cells, e.g. embryonic stem cells. The use of these cells would depend on their availability/accessibility, the techniques available to grow them, the risks involved in harvesting them without the depletion of the

donor cells, success in growing them without altering their nature and transplanting them back into the retina.

The progenitor cells of the retina (neural precursor cells)<sup>15-16</sup> do have the potential to constitutively replace the different cells of retinal-like neurons, photoreceptors, and glial cells. This approach could be useful in developing and studying the pathobiology of the stem cells in health and disease, but the technical difficulty in obtaining these cells and their limited availability could be an issue. The ciliary and iris pigment progenitor cells contain a mitotically quiescent population of neural progenitors that proliferate to make neural stem cells, with a potential for self-renewal.<sup>17-18</sup> Experiments have documented the incorporation of these cells into injured retina, but not normal retina, suggesting that functional integration is possible in damaged tissues. Neural progenitor cells from the brain can restore and survive in the damaged retina,<sup>19</sup> but the major limitation is the source of these cells, which is as rare as, or even rarer than, the retinal cells themselves. It has been shown that bone marrow stromal cells can differentiate into retinal cells in injured rat retina, show functional recovery, and also promote or inhibit retinal angiogenesis.<sup>20-23</sup> Similarly, embryonic stem cells (ESCs) were shown to survive, migrate and integrate into the host retina,<sup>24-25</sup> but they do pose a potential risk of tumour-induction after engraftment.

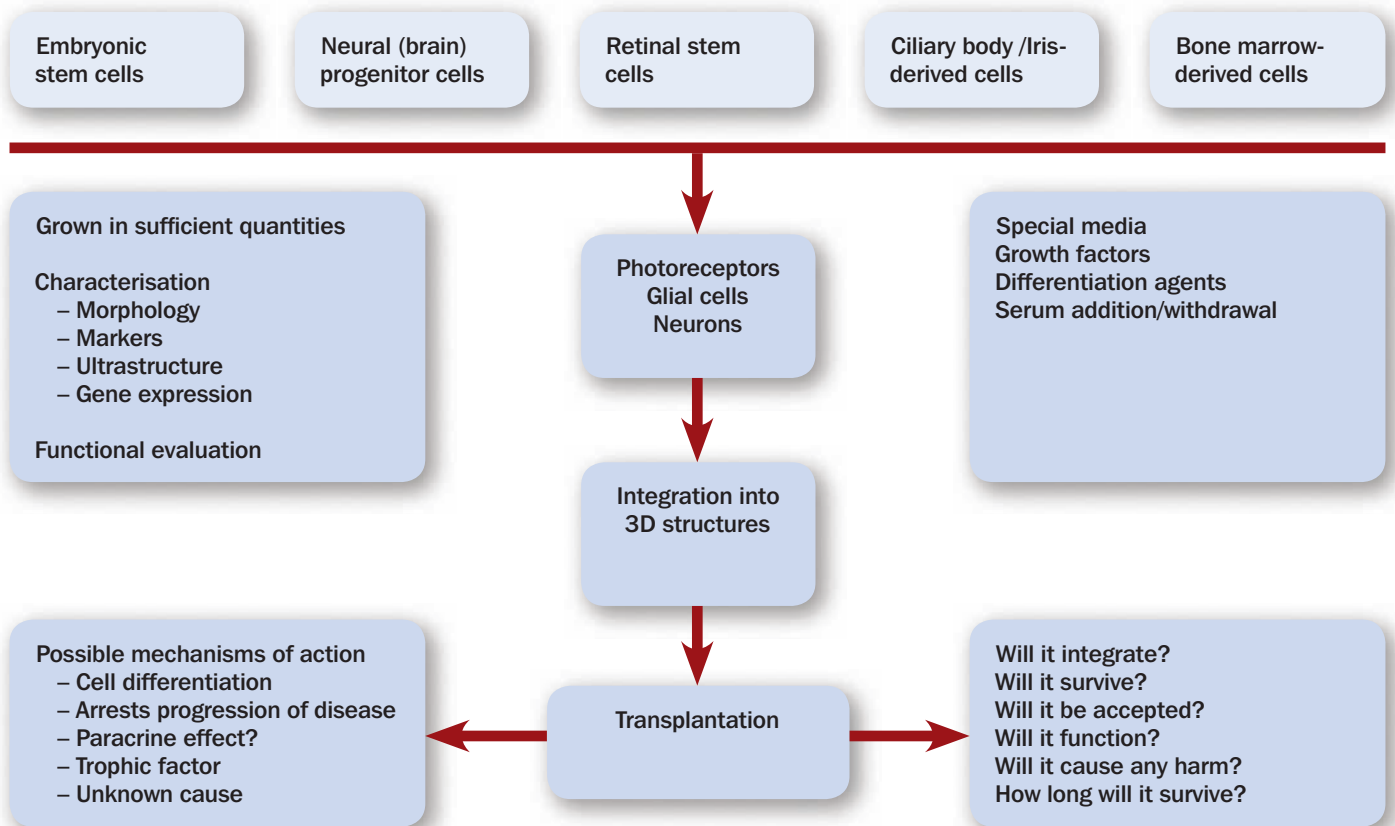
## Do we need cells or three-dimensional structures?

The question that now arises is: should we deliver the cells into the target site and hope for the damaged tissue to help in the final integration of the transplanted cells, or should we attempt to organise the cells into tissues before transplantation? A 3D tissue architecture not only provides anatomic integration of cells but also improves the functional outcome.<sup>26</sup> The cells could also be delivered on polymer substrates to the subretinal space, so as to improve their survival, migration and functional restoration.<sup>27</sup>

## Will the cells integrate?

Now, assuming the cells and the tissues are ready to generate retina, will they integrate into the adult retina? Unlike the clinical application of cultivated epithelial cells for ocular surface reconstruction, the use of neural cells poses tough challenges. More rigid proof of integration of these cells is warranted. Successful cell therapy should fulfill the following criteria: the desired cells

**Figure 1. Thematic approach to growing retinal cells for potential clinical transplantation**



should multiply/grow in sufficient quantities, organise into functional units, survive and integrate into the host, and ultimately, function appropriately in a safe manner.

## Ethical issues

Clinicians and researchers must constantly deal with the question of adequacy of proof in animal experiments, before moving to human clinical trials. Though a few clinical trials were conducted using foetal cells, there are no published trials using any other cells for clinical transplantation. Reviewing the progress in all fields, it appears that the bone marrow-derived cells have the advantage of being autologous, with proven clinical safety. They could therefore be considered for a pilot study after seeking the approval of regulatory bodies, the Institutional Review Board clearance and patients' informed consent.

## Conclusion

In summary, when permanently damaged, the retinal cells which are specialised neurons, cannot be rescued or repaired in the natural process and therefore warrant cell therapy in future.

## References

- Lolley RN, Rong H, Craft CM. Linkage of photoreceptor degeneration by apoptosis with inherited defect in phototransduction. *Invest Ophthalmol Vis Sci.* 1994; 35: 358-62.
- Narfstrom K, Katz ML, Bragadottir R, Seeliger M, Boulanger A, Redmond TM, et al. Functional and structural recovery of the retina after gene therapy in the RPE65 null mutation dog. *Invest Ophthalmol Vis Sci.* 2003; 44: 1663-72.
- Le Meur G, Weber M, Pereon Y, Mendes-Madeira A, Nivard D, Deschamps JY, et al. Postsurgical assessment and long-term safety of recombinant adeno-associated virus-mediated gene transfer into the retinas of dogs and primates. *Arch Ophthalmol.* 2005; 123: 500-6.
- Chong NH, Alexander RA, Waters L, Barnett KC, Bird AC, Luthert PJ. Repeated injections of a ciliary neurotrophic factor analogue leading to long-term photoreceptor survival in hereditary retinal degeneration. *Invest Ophthalmol Vis Sci.* 1999; 40: 1298-305.
- Bush RA, Lei B, Tao W, Raz D, Chan CC, Cox TA, et al. Encapsulated cell-based intraocular delivery of ciliary neurotrophic factor in normal rabbit: dose-dependent effects on ERG and retinal histology. *Invest Ophthalmol Vis Sci.* 2004; 45: 2420-30.
- Margalit E, Maia M, Weiland JD, et al. Retinal prosthesis for the blind. *Surv Ophthalmol.* 2002; 47: 335-356.
- Rizzo JF, III, Wyatt J, Loewenstein J, Kelly S, Shire D. Perceptual efficacy of electrical stimulation of human retina with a microelectrode array during short-term surgical trials. *Invest Ophthalmol Vis Sci.* 2003; 44: 5362-5369.
- Pellagrini G, Traverso EC, Franzi TA. Long term restoration of damaged corneal surfaces with autologous cultivated corneal epithelium. *Lancet*1997; 349: 990-993.
- Tsai RJ, Li LM, Chen JK. Reconstruction of damaged corneas by transplantation of autologous limbal epithelial cells. *N Engl J Med* 2000; 343: 86-93.
- Koizumi N, Inatomi T, Suzuki T, Sotozono C, Kinoshita S. Cultivated corneal epithelial stem cell transplantation in ocular surface disorders. *Ophthalmology* 2001; 108: 1569-74.
- Sangwan VS, Vemuganti GK, Singh S, Balasubramanian D. Successful reconstruction of damaged ocular outer surface in humans using limbal and conjunctival stem cell culture methods. *Biosci Rep.* 2003; 23: 169-74.
- Vemuganti GK, Kashyap S, Sangwan VS, Singh S. Ex-vivo potential of cadaveric and fresh limbal tissues to regenerate cultured epithelium. *Indian J Ophthalmol* 2004; 52: 113-20.
- Sangwan VS, Matalia HP, Vemuganti GK, Ifthekar G, Fatima A, Singh S, Rao GN. Early results of penetrating keratoplasty after cultivated limbal epithelium transplantation. *Arch Ophthalmol.* 2005; 123: 334-40.
- Pittenger MF, Mackay AM, Beck SC, Jaiswal RK, Douglas R, Mosca JD, et al. Multilineage potential of adult human mesenchymal stem cells. *Science* 1999; 284: 143-7.
- Mayer EJ, Carter DA, Ren Y, Hughes EH, Rice CM, Halfpenny CA, et al. Neural progenitor cells from postmortem adult human retina. *Br J Ophthalmol.* 2005; 89: 102-6.
- Coles BL, Angenieux B, Inoue T, Del Rio-Tsonis K, Spence JR, McInnes RR, et al. Facile isolation and the characterization of human retinal stem cells. *Proc Natl Acad Sci U S A.* 2004; 101: 15772-7.
- Ahmad I, Tang L, Pham H. Identification of neural progenitors in the adult mammalian eye. *Biochem Biophys Res Commun.* 2000; 270: 517-21.
- Haruta M, Kosaka M, Kanegae Y, Saito I, Inoue T, Kageyama R, et al. Induction of photoreceptor-specific phenotypes in adult mammalian iris tissue. *Nat Neurosci.* 2001; 4: 1163-4.
- Young MJ, Ray J, Whiteley SJ, Klassen H, Gage FH. Neuronal differentiation and morphological integration of hippocampal progenitor cells transplanted to the retina of immature and mature dystrophic rats. *Mol Cell Neurosci.* 2000; 16: 197-205.
- Tomita M, Adachi Y, Yamada H, Takahashi K, Kiuchi K, Oyaizu H, et al. Bone marrow-derived stem cells can differentiate into retinal cells in injured rat retina. *Stem Cells.* 2002; 20: 279-83.
- Otani A, Kinder K, Ewalt K, Otero FJ, Schimmel P, Friedlander M. Bone marrow-derived stem cells target retinal astrocytes and can promote or inhibit retinal angiogenesis. *Nat Med.* 2002; 8: 1004-10.
- Otani A, Dorrell MI, Kinder K, Moreno SK, Nusinowitz S, Banin E, et al. Rescue of retinal degeneration by intravitreally injected adult bone marrow-derived lineage-negative hematopoietic stem cells. *J Clin Invest.* 2004; 114: 765-74.
- Kicic A, Shen WY, Wilson AS, Constable UJ, Robertson T, Rakoczy PE. Differentiation of marrow stromal cells into photoreceptors in the rat eye. *J Neurosci.* 2003; 23: 7742-9.
- Hara A, Niwa M, Kunisada T, Yoshimura N, Katayama M, Kozawa O, et al. Embryonic stem cells are capable of generating a neuronal network in the adult mouse retina. *Brain Res.* 2004; 999: 216-21.
- Meyer JS, Katz ML, Maruniak JA, Kirk MD. Neural differentiation of mouse embryonic stem cells in vitro and after transplantation into eyes of mutant mice with rapid retinal degeneration. *Brain Res.* 2004; 1014: 131-44.
- Dutt K, Harris-Hooker S, Ellerson D, Layne D, Kumar R, Hunt R. Generation of 3D retina-like structures from a human retinal cell line in a NASA bioreactor. *Cell Transplant.* 2003; 12: 717-31.
- Tomita M, Lavik E, Klassen H, Zahir T, Langer R, Young MJ. Biodegradable polymer composite grafts promote the survival and differentiation of retinal progenitor cells. *Stem Cells.* 2005; 23: 1579-88.

## Cell therapy glossary

### Adult stem cells

Undifferentiated cells found in most adult tissues. Adult stem cells can renew themselves and differentiate to yield all the specialised cell types of the tissue from which they originated. Also referred to as 'somatic stem cells'.

### Cell-based therapies

Treatment in which stem cells are induced to differentiate into the specific cell type required to repair damaged or depleted adult cell populations or tissues.

### Cellular therapy

A new way to treat disease and injury. It aims to repair damaged and diseased body-parts with healthy new cells provided by stem cell transplants.

### Cones

A type of specialised light-sensitive cells (photoreceptors) in the retina that provide sharp central vision and colour vision. See also Rods.

### Differentiation

The process whereby an unspecialised early embryonic cell acquires the features of a specialised cell, such as a heart, liver, or muscle cell.

### Embryonic stem cells

Primitive (undifferentiated) cells from the embryo that have the potential to become all cell types found in the body (totipotent). Embryonic stem cells (ESCs) are derived from four to five day-old embryos.

### Gene therapy

Therapy aimed at counteracting the gene defect by substituting normal gene material at the site of the problem.

### Mesenchymal stem cells

Stem cells found primarily in the bone marrow that can transform into bone, cartilage, fat, and connective tissue. These cells are also referred to as bone marrow stromal cells.

### Multipotent stem cells

Stem cells that can give rise to several other cell types, but those types are limited in number. An example of multipotent cells is haematopoietic cells – blood stem cells that can develop into several types of blood cells.

### Photoreceptors

Cells that are sensitive to light.

### Plasticity

The ability of stem cells from one adult tissue to generate the differentiated cell type of another.

### Progenitor cells

Cells that can produce only one cell. They can differentiate into a limited number of cell types, but cannot make more stem cells (or renew themselves).

### Proliferation

Expansion of a population of cells by the continuous division of single cells.

### Regenerative medicine

A treatment in which stem cells are induced to differentiate into the specific cell type required to repair damaged or depleted adult cell populations or tissues.

### Retina

The light-sensitive layer of tissue that lines the back of the eyeball; sends visual messages through the optic nerve to the brain.

### Retinal pigment epithelium

The pigment cell layer that nourishes the retinal cells; located just outside the retina and attached to the choroid.

### Rods

A type of specialised light-sensitive cells (photoreceptors) in the retina that provide side vision and the ability to see objects in dim light (night vision). Also see Cones.

### Stem cells

Unspecialised cells that serve as the source, or 'stem', for specialised cells like heart, brain, or blood cells. They have two important characteristics that distinguish them from other cells in the body. Firstly, they can replenish their numbers for long periods through cell division. Secondly, after receiving certain chemical signals, they can differentiate, or transform into specialised cells with specific functions, such as a heart cell or nerve cell. Found in days-old embryos and a few adult organs.

### Subfoveal

Beneath the fovea, the central pit in the macula that produces the sharpest vision.

### Undifferentiated cells

Cells that have not changed to become a specialised type of cell.

## REPORT

# What will be new

## Shaheen Shah reports from the World



### Shaheen Shah

Clinical Research Fellow, International Centre for Eye Health, London School of Hygiene & Tropical Medicine, Keppel Street, London WC1E 7HT, UK.

**The World Ophthalmology Congress was held from February 19-24, 2006 in Brazil. I took the opportunity to ask some leading experts how they think the diagnosis and management of posterior segment conditions might be different in the future, specifically in the year 2020. What follows is a summary of their views, which we hope will generate interest and lively discussion amongst our readers and their colleagues.**

## Diabetic retinopathy

Dr Alexander Brucker, Professor of Ophthalmology at the University of Pennsylvania and Editor of the journal *Retina*, suggests that by the year 2020, decisions about treatment will be based on diagnosis using high definition optical coherence tomography (OCT) visualisation of the retina, in conjunction with fluorescein angiography (FA). Although the interpretation of the clinical findings may be similar, management will be more pharmacologically directed. He anticipates change will also be effected through alteration of the patient's individual risk factor profile. For proliferative disease, the treatment will probably continue to be with panretinal laser photocoagulation, but the addition of new pharmacologic agents (e.g. anti-Vascular Endothelial Growth Factor or anti-VEGF) could reduce the requirement for this destructive treatment.

According to Dr Alistair Laidlaw, Consultant Vitreoretinal Specialist at St Thomas' Hospital, London, UK, the prevention of diabetic retinopathy through effective screening will take priority. He foresees an increased use of non-mydriatic, wide-field, low-light systems, which will make screening comfortable and effective. Management will be through improved medical care of diabetes overall, and use of newer agents (e.g. protein kinase C inhibitors) as well as further developments in non-destructive laser systems.

## Retinopathy of prematurity (ROP)

Dr Rajvardhan Azad, Professor of Ophthalmology and Head of Vitreo-Retinal and ROP unit at the Dr R.P. Centre for Ophthalmic Sciences, New Delhi, predicts that by 2020, there will be increased awareness of the condition amongst ophthalmologists and neonatologists through better, easier and more cost-effective imaging of the retina (e.g. RetCam).



# at the back of the eye in the year 2020?

## Ophthalmology Congress

These imaging systems will also improve diagnosis and therefore subsequent management. Therapies will include increased use of angiostatic agents, and more focal, less destructive laser treatments. The current belief that surgical techniques do not work will change as advances in techniques develop (e.g. use of plasminogen to liquefy the vitreous to reduce the traction).

Dr Clare Gilbert, Reader in International Eye Health at the London School of Hygiene and Tropical Medicine, believes that clinical trials currently underway (e.g. optimum oxygen concentrations for premature babies) will help to reduce the incidence of sight-threatening disease. Until now, detection of ROP has been performed by ophthalmologists using indirect ophthalmoscopy, but in the future digital imagery (taken by non-ophthalmologists) with automated image analysis, or remote (telemedicine) expert reading, will offer the possibility of screening in the true sense of the word. Regarding management, she believes that, as with other vasoproliferative eye conditions, there will be medical treatments that block the disease from progressing. The current use of ablation techniques will be kept to a minimum.

## Retinoblastoma

Dr Carol Shields, Professor of Ophthalmology and Co-Director of the Oncology Service at the Wills Eye Hospital, Philadelphia, foresees earlier detection of cases through increased awareness (e.g. routine screening of the red reflex) which will potentially identify the sporadic cases. A change in chemotherapy treatment from systemic to local delivery will reduce overall side-effects. New developments in slow-release mechanisms (e.g. a reservoir system inserted into the sub-Tenon space which can then be regularly filled with chemotherapeutic agent) and increased use of adjunctive treatments (e.g. locally placed anti-proliferative agents like combretastatin), will further improve treatment success.

Dr Alejandra A. Valenzuela of the Royal Children's Hospital, University of Queensland, Australia, considers that by 2020, better education and increased surveillance by the health community will be fundamental to earlier diagnosis and successful outcomes. Multimodal therapeutic advances will save not only the life of the patient, but also preserve the eye and, in some cases, preserve the vision. The addition of gene therapy to the particular Rb1 mutation affecting some children may provide a further avenue in management.

## Retinal detachments

Dr Yasuo Tano, Professor of Ophthalmology, University of Osaka, President of Asia-Pacific Academy of Ophthalmology,



Shaheen Shah

The entrance to the World Ophthalmology Congress

envisages that pars plana vitrectomy (PPV) will take over as the primary choice for detachment repair. Improved imaging with 3-dimensional OCT high resolution imaging will improve visualisation of the posterior segment. Non-vitrectomising macular surgery may offer the hope of non-accelerated progression of nuclear cataract that currently occurs following PPV. Bimanual techniques for surgery are also likely to be more widespread.

Dr G W Aylward, Medical Director at Moorfields Eye Hospital, London, foresees no significant change in the diagnostic and management techniques for routine retinal detachments, as reattachment rates currently reach 90 per cent. He suggests that the main thrust by the year 2020 will be focused at the public health level, such as alerting the public to early symptoms and signs in order to 'catch' detachments before the macula is affected.

Dr Borja Corcostegui, President of Española de Retina y Vítreo (SERV) and Director of Instituto de Microcirugía Ocular (IMO), Barcelona, added that, as the posterior segment diseases are better understood (particularly the vascular disorders), the range of conditions that require surgery and indications for intervention would be quite different in 2020.

## Age-related macular degeneration (AMD)

Dr. Rosario Brancato, Professor of Ophthalmology, University San Raffaele, Milan, Italy and Editor of the *European Journal of Ophthalmology*, predicts that diagnosis for AMD will be directed at three levels:

- Understanding pathological angiogenic mechanisms
- Understanding these effects in the local tissue
- Epidemiological and genetic research regarding predispositions to AMD.

FA, Indocyanine Green (ICG) angiography and OCT will continue to prove useful for diagnosis and monitoring evolution of the disease.

Treatments will be directed by the diagnosis and will specifically target the pathogenic mechanisms. In this regard, finding an effective drug for the prevention and the regression of pathological neovascularisation will be important. Research and development into regenerative therapies will also increase in importance. An important challenge will also be to identify the best delivery systems for these medications (e.g. oral, subconjunctival, even topical).

## Retinal dystrophies, e.g. retinitis pigmentosa

Dr Ian Constable, Professor of Ophthalmology, University of Western Australia and Director of Lions Eye Institute, Perth, believes that by the year 2020, the range of specific gene defects will have been documented for the various clinical phenotypes. Gene function (e.g. enzymatic, cell signaling) for most dystrophies will also be understood, and animal models in place. Gene therapies will predominantly be available for large families or populations, however there will be some scope for developing customised treatments. In general, the strategy will be:

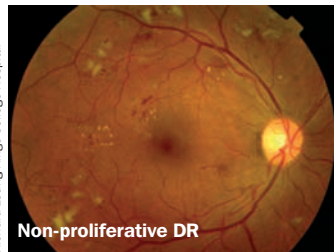
- Autosomal recessive – replace the defunct gene
- Autosomal dominant – insert a separate gene.

Dr Richard Gisbert, Professor of Ophthalmology, University of Hamburg and co-founder of the European Society of Retinal Specialists (EURETINA), foresees potential treatment options for retinal dystrophies in the future to include cell replacement strategies (i.e. transplantation of stem cells, progenitor cells, primary retinal cells or retinal tissue), gene therapy, and, for advanced cases, electronic retinal prostheses.

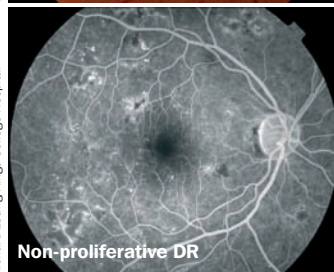
# Back of the eye glossary

## Diabetic retinopathy (DR)

Diabetic retinopathy can be subdivided into two basic forms:



Non-proliferative DR



Non-proliferative DR

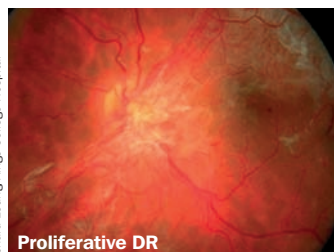### 1. Non-proliferative

Non-proliferative disease can be identified by a number of clinical findings: microaneurysms, 'dot and blot' haemorrhages, cotton wool spots.

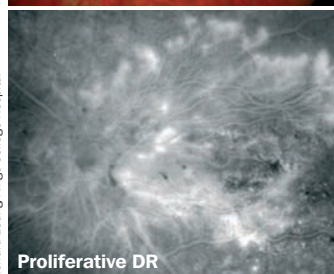
Clinically significant macular oedema (CSME) is defined as:

- Retinal thickening within 500 microns of the centre of the fovea
- Hard exudation within 500 microns of the centre of the fovea if associated with retinal thickening
- Retinal thickening of one disc area, any part of which is located within one disc diameter (1,500 microns) from the centre of the fovea.

Eyes with CSME benefit from focal/grid laser photocoagulation to the macula.



Proliferative DR



Proliferative DR

### 2. Proliferative

In proliferative diabetic retinopathy, the eyes demonstrate,

singularly or in combination, neovascularisation of the disc (NVD), neovascularisation of the retina (neovascularisation elsewhere NVE), or neovascularisation of the iris (NVI) capillaries and veins.

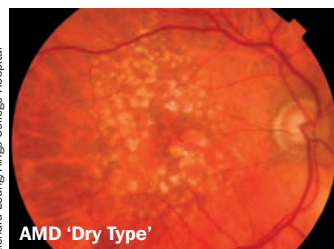
High-risk characteristics include:

- NVD greater than or equal to one fourth to one third of a disc area (one quarter of a disc area in eyes with large optic discs and one third of a disc area in eyes with small optic discs)
- NVD of any size associated with preretinal or vitreous bleeding
- NVE at least 0.5 disc area and associated with preretinal or vitreous bleeding.

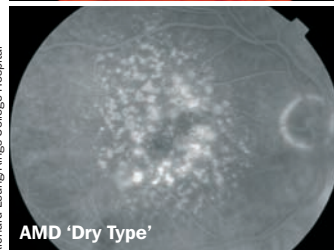
Eyes of high-risk characteristics benefit from panretinal laser photocoagulation.

## Age-related macular degeneration (AMD)

Age-related macular degeneration (AMD) is a progressive deterioration of Bruch's membrane, retinal pigment epithelial, choriocapillaris, and outer retina in the macular area. There are two variants:



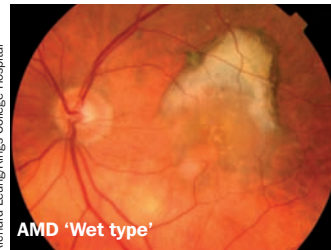AMD 'Dry Type'



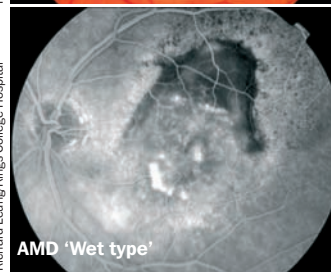
AMD 'Dry Type'

**1. 'Dry Type':** Drusen and associated retinal pigment epithelial changes (atrophy and clumping). The majority of these eyes have moderate visual disturbance. Extensive or 'geographic' atrophy of the retinal pigment epithelium, however, can result in marked visual acuity loss.

**2. 'Wet or Exudative Type':** Choroidal neovascularisation (or 'membrane') with associated fluid, lipid exudate, and haemorrhage under either the retinal pigment epithelium or neurosensory retina. This typically causes moderate to severe loss



AMD 'Wet type'



AMD 'Wet type'

of central vision. The natural history is poor, often leading to subretinal fibrosis and scarring. This type can be further divided into the 'classic' membrane and the 'occult' membrane using fluorescein angiography.

## Retinopathy of prematurity (ROP)

The condition was initially referred to as retrolental fibroplasia. There are five stages in classification:

**Stage 1** is defined as a thin structure within the plane of the retina that separates vascularised from avascular retina.


**Stage 2** represents an elevated ridge that has extended beyond the plane of the retina.

**Stage 3:** there is extraretinal fibrovascular proliferation or neovascularisation at the ridge.

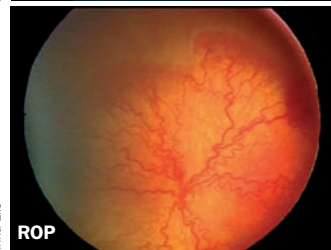**Stage 4:** there is a partial traction-like retinal detachment.

**Stage 5** is defined as a total retinal detachment in an open or closed funnel configuration.

The term 'plus disease' denotes



ROP

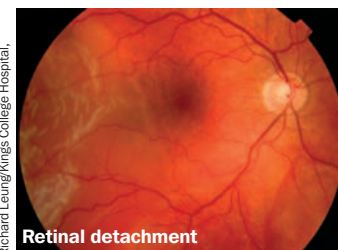

ROP

significantly dilated and tortuous retinal vessels in the posterior pole. It indicates extensive vascular incompetence, and can be associated with vitreous haze, iris vessel engorgement, and poor pupillary dilation. 'Plus disease' is a poor prognostic sign in ROP.

## Retinal detachment

A retinal detachment occurs when the retina's neurosensory layer and pigment epithelial layers separate. There are three



Retinal detachment

types of retinal detachments:

### Rhegmatogenous

This is the most common type and occurs when there is a break in the sensory layer of the retina, and liquefied vitreous seeps underneath, causing the two layers of the retina to separate.

### Tractional

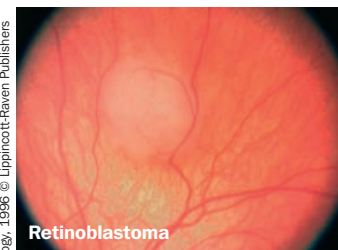
The second most common type occurs when strands of vitreous or scar tissue create traction on the retina, pulling it loose.

### Exudative

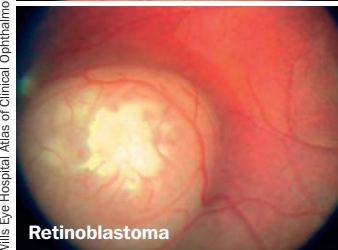
This results from an accumulation of fluid under an intact neurosensory retina. This usually occurs in conjunction with another disease, e.g posterior scleritis, choroidal inflammatory conditions and neoplasms.

## Retinoblastoma

Retinoblastoma is a primary malignant intraocular neoplasm that arises from immature retino-



Retinoblastoma



Retinoblastoma

Richard Leung/Kings College Hospital

Richard Leung/Kings College Hospital

Richard Leung/Kings College Hospital

Richard Leung/Kings College Hospital

Richard Leung/Kings College Hospital

Richard Leung/Kings College Hospital

Richard Leung/Kings College Hospital

Richard Leung/Kings College Hospital

Anna Ellis

Anna Ellis

Willis Eye Hospital Atlas of Clinical Ophthalmology, 1996 © Lippincott-Raven Publishers

# Cochrane Eyes and Vision Group (CEVG) systematic review activity on posterior segment treatments



## Cochrane Eyes and Vision Group

International Centre for Eye Health, London School of Hygiene & Tropical Medicine, Keppel Street, London, WC1E 7HT, UK.

The following list presents the current evidence on back of the eye treatments, as well as reviews which are planned or underway. All Cochrane reviews and protocols are completed using strict methodology and are peer-reviewed at both protocol and review stage. They are published in *The Cochrane Database of Systematic Reviews*, one of several databases in *The Cochrane Library*.

## Published reviews

A published review follows a structured format detailing, among other things, methods used, inclusion/exclusion criteria, search strategies for finding randomised controlled trials, and meta-analysis (where performed). CEVG-published reviews relevant to back of the eye treatments are:

- Antioxidant vitamin and mineral supplements for age-related macular degeneration
- Antioxidant vitamin and mineral supplements for preventing age-related macular degeneration
- Ginkgo Biloba extract for age-related macular degeneration
- Interventions for acute central retinal artery occlusion
- Interventions for asymptomatic retinal breaks and lattice degeneration for preventing retinal detachment
- Laser photocoagulation for choroidal neovascularisation in pathologic myopia
- Non-steroidal anti-inflammatory agents for treating cystoid macular oedema following cataract surgery
- Photodynamic therapy for neovascular age-related macular degeneration
- Radiotherapy for exudative age-related macular degeneration.

## Published protocols

A published protocol outlines the background, rationale and methods of the review. CEVG-published protocols relevant to back of the eye treatments are:

- Antiangiogenic therapy with anti-VEGF modalities for neovascular age-related macular degeneration
- Haemodilution treatment for retinal vein occlusion
- Interventions for acute retinal necrosis
- Intravitreal steroids for macular oedema in diabetes
- Laser photocoagulation for neovascular age-related macular degeneration
- Surgical implantation of steroids with antiangiogenic characteristics for treating exudative macular degeneration.

## Working titles

A working title is a protocol in progress prior to being submitted for publication. Working titles dealing with back of the eye treatments currently registered with CEVG are:

- Acupuncture for age-related macular degeneration
- Blood pressure control for the management of diabetic retinopathy
- Calcium dobesilate for diabetic retinopathy
- Carbonic anhydrase inhibitors for cystoid macular oedema
- Chinese herbal treatment for diabetic retinopathy
- Fish oils and vitamin A for hereditary retinal disease
- Intravitreal steroid for retinal vein occlusion
- Laser photocoagulation for retinal vein occlusion
- Laser treatment for diabetic retinopathy
- Laser treatment of drusen in age-related macular degeneration
- Pars plana vitrectomy for diabetic macular oedema
- Pharmacotherapy for preventing proliferative vitreoretinopathy in retinal detachment surgery
- Statins for age-related macular degeneration
- Sub-threshold laser treatment for diabetic maculopathy
- Surgical interventions for repairing simple rhegmatogenous retinal detachments
- Tamponade in surgery for retinal detachment associated with proliferative vitreoretinopathy
- Traditional Chinese medicine for retinitis pigmentosa.

## Available titles

CEVG invites people from around the world interested in preparing a review on the following titles that do not have authors. Available titles for CEVG reviews in the area of back of the eye treatments are:

- Interventions for cytomegalovirus retinitis
- Sub-macular surgery for age-related macular degeneration.

## Access to Cochrane systematic reviews

*The Cochrane Library* is available by subscription, either on CD-ROM or via the internet. Residents in a number of countries, including Australia, New Zealand and South Africa, can access the *Library* free of charge through a 'national provision'. Higher Education and Further Education residents can access the *Library* using an Athens password.

## Further information

You can either visit the CEVG website at [www.cochraneeyes.org](http://www.cochraneeyes.org) or email Anupa Shah, Review Group Co-ordinator at [cevg@lshtm.ac.uk](mailto:cevg@lshtm.ac.uk)

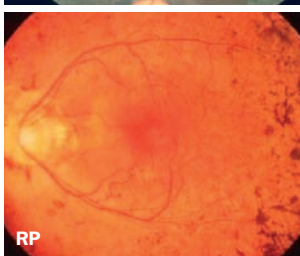
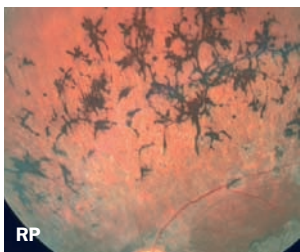
blasts within the developing retina. It is the most common primary intraocular malignancy of childhood. Most cases occur in children younger than six years of age.

The most common presenting symptoms of retinoblastoma are leukocoria (a white pupil), in the tumour-containing eye or eyes, strabismus or symptomatic or asymptomatic visual loss. Retinoblastoma can be hereditary.

## Retinal dystrophies – Retinitis pigmentosa (RP)

A group of hereditary retinal conditions that cause degeneration of the retina.

Retinal cells are among the most specialised cells in the human body and depend on a number of unique genes to create vision. A disease-causing mutation in any one of these genes can lead to vision loss. RP results from a large and as yet unknown number of gene defects, of which around a hundred have been found so far. RP can be passed to succeeding generations by one of three genetic inheritance patterns: autosomal dominant, autosomal recessive, or X-linked inheritance. RP causes the degeneration of photoreceptor cells from the outer edges of the retina, causing a progressive loss of peripheral vision, night blindness and reduced or absent electroretinogram (ERG) recordings.





# How to prescribe spectacles for presbyopia

## What is presbyopia?

As we grow older, the lens loses the ability to focus at close distances. Starting around the age of 40, near vision will slowly become worse, but distance vision will not be affected. Spectacles for near vision can help a person see clearly for tasks such as sewing, carving or reading.

### Indications

People with presbyopia usually say that their near vision has slowly become worse.

### You will need

- Distance and near vision charts with letters, Es or shapes
- Pinhole (optional)
- A trial set of lenses or a selection of ready-made spectacles (RMS). Most people with presbyopia do not need spectacles with powers of less than +1.00 or more than +3.00. See Table 1 for suggested powers.

**Table 1. Suggested lens powers for correction of presbyopia**

+1.00	Weaker power
+1.50	
+2.00	
+2.50	
+3.00	
+3.50	
+4.00	Stronger power

### Preparation

Before prescribing spectacles, make sure there is nothing else wrong with the person's eyes.

- **Measure distance vision.** If presenting vision is 6/18 (6/12 if they drive) or worse in either eye, do not prescribe spectacles without further tests. If vision does NOT improve to at least 6/9 with pinhole, the person needs an eye health check. If vision DOES improve to at least 6/9 with pinhole,

the person needs an eye test for distance vision

- **Ask about health.** Several diseases pose related eye problems. Affected patients should always have an eye health check.

### Method

The correct power of spectacles for presbyopia depends on the person's age, the distance at which they want to see for near work, and how well they can see.

**1 Take a detailed history.** Write down the person's age and medical history and symptoms. Find out if there is a general medical history of diabetes, hypertension, thyroid disease, rheumatoid arthritis, or other eye disease.

**2 Find out the person's working distance,** that is the distance at which they would like to do most of their near work.

- Find out what kind of near work (see Figure 1) the person does
- Ask him or her to hold a near vision chart at the distance they do most near tasks. Around 40 cm is a comfortable distance for most people.

### 3 Measure near vision

- The person holds the near chart at their working distance with both eyes open. Ask them to read the smallest line or show the smallest shapes they can see clearly. Write this down as their near visual acuity (e.g. N8 or J6)
- If the person already has spectacles for presbyopia, measure their near vision with these being worn. Write this down as 'near visual acuity with spectacles'
- If the person is able to see N8 or better without any spectacles, they might not need spectacles for presbyopia. If they can see N8 or better with their old spectacles, they might not need new spectacles.

### 4 Identify the correct lens power

- Look up the person's age in Table 2 and select the power to try first.

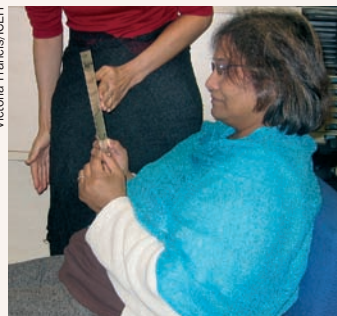**Table 2. Suggested lens power for different ages**

Person's age	Lens power
35 to 45	+1.00
45 to 50	+1.50
50 to 55	+2.00
Over 55	+2.50 or higher

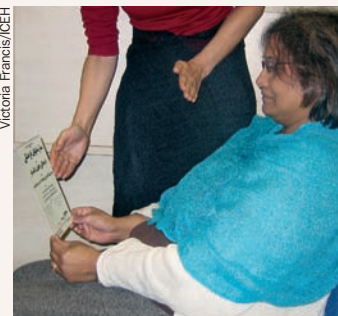
- **Measure near vision with the selected power** spectacles or trial lenses. Give the person the near chart to hold at the distance they would like to see clearly. Ask him or her to show the smallest line they can see. If the person cannot see at least the N8 line, try the next stronger power
- **Check the range of clear vision.** Many people will have good vision using the approximate power, but some may not. If you want to make sure that the lens power is suitable for that individual, check that the person's range of clear vision with the lens power is correct. The range of clear vision is the distance between the closest that a person can see clearly and the furthest that they can see clearly. The range is achieved by trying out the testing at various distances
- Ask the person to look at the smallest line they can see on the near chart and then bring the chart closer until the letters become blurred. Hold one hand to mark the closest distance (Figure 2a), then ask the person to move the chart further away until the letters become blurred. Mark the furthest distance (Figure 2b)
- Ask the person to hold the chart at the distance they want to see clearly. This is the working distance. If the range is correct, the working distance should be in the middle of this range, for example at about 40 cm (Figure 2c). This means that a person will be able to see clearly for the same distance in front and behind their working distance
- The power is correct if the middle point of the range is the same as the working distance. If the middle point of the range is further away than the person's preferred working distance, try one stronger (higher)



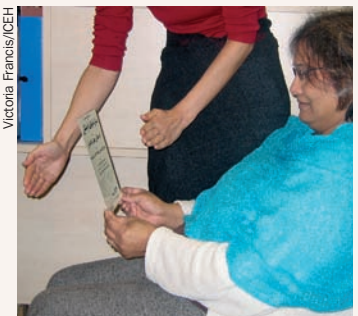**Figure 1. Woman demonstrates her working distance**



**Figure 2a.**



**Figure 2b.**



**Figure 2c.**

Checking the range of clear vision



**Rènée du Toit**

Eye Care Education and Evaluation Consultant, PO Box 891, Randwick, 2031, NSW, Australia.

power to move the range (and working distance) closer. If the middle point of the range is closer than the person's preferred working distance, try one weaker (lower) power to move the range (and working distance) further away. Test the range again, until the power is correct, i.e. the middle point of the range = working distance. Write down the power of the lenses and the near visual acuity with these lenses

- If the person cannot read N10 on the near vision chart with any power lenses, they need further eye checks.

**5 Before prescribing spectacles, note:**

- **Approximate lens powers, based on age, will not be suitable for all.** A weaker lens power than expected for a person's age, or no presbyopic lenses, might be needed if a person has myopia (short-sightedness). They should remove their distance spectacles if they want to see at a close distance. A lens power stronger than expected for the person's age may be needed if the person has hyperopia (far-sightedness), low vision, wants to work at a distance closer than 40 cm, or to see very small objects, for example, a 48 year-old man may like to make jewellery at 25 cm, so might need +2.00
- **Do not prescribe a power that is too high.** If there is no difference in the near vision when a person looks through a +0.50 stronger power, do not prescribe the stronger power. This is because if the power is stronger than needed, the person will have to hold things too close to their eyes. Also, most people would like to see at their near working distance as well as a little further away. For example, a woman may mainly want to see her sewing at 40 cm, but holds a book at 50 cm and chops vegetables at 60 cm
- **A change in spectacles** is usually only necessary if the person needs at least 0.50 stronger than their old spectacles, has received spectacles for presbyopia about two years ago, or can see better with the new spectacles than their old spectacles.

**6 Select the type of lenses** that would be best for the person. Table 3 describes the options.

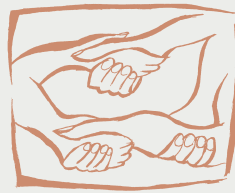**Table 3. Types of lenses**

Types of lenses	Advantages	Disadvantages
Single vision (Ready-made, near or reading spectacles)	Less expensive	The person will see clearly at near but their distance vision will be blurred when they look up
Bifocal lenses and Multifocal lenses (varifocal)	Useful if a person has a distance refractive error and presbyopia, or if they need to see clearly at distance and near	Usually more expensive than single vision spectacles for presbyopia, and may take longer to acquire

**7 Adjust the spectacles and explain how to use them.** Before the person leaves with their new spectacles:

- Adjust spectacles to fit properly and feel comfortable
- Explain the use of spectacles for presbyopia and that it may take a little time to get used to them. Tell them to come back if they experience any problems
- Explain how to look after the spectacles so that the lenses do not become scratched. Advise them to wash the spectacles daily with soap and water and wipe with a clean cloth.

**8 Remind them to return in about two years** to check if they need new spectacles to see more clearly at close distances.



**EXCHANGE**

**An inexpensive tool for routine fundus examination at primary eye care centres**

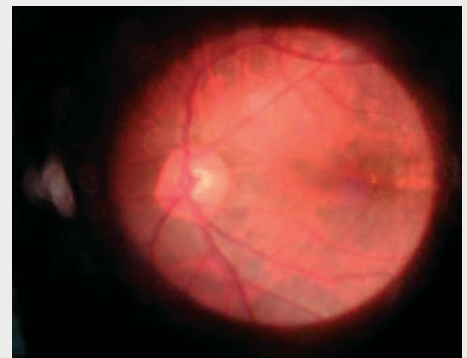
**Dr P Namperumalsamy**

Vice Chairman, Aravind Eye Care System, Madurai, 625020, India.

Conventional fundus photography uses a fundus camera. It is very expensive and found only in tertiary care eye hospitals. If changes in the retina, due to diabetic retinopathy, and changes in optic disc, due to glaucoma, can be detected early, treatment will prevent further loss of vision. To provide an inexpensive tool for the routine examination of the fundus at primary eye care centres, we use a simple attachment to mount a modern digital camera on a slit lamp. Using the slit lamp and a 78 or 90 dioptre lens we can get good fundus pictures. The arrangement is so simple that a trained paramedic can take the picture, copy it onto a computer, and transmit it to a retina specialist through email for further examination and follow up action that may be required.

The picture shown in Figure 1 was taken at the Bodinayakanur Vision Centre and was transmitted to Aravind Eye Hospital, Madurai.

The picture was taken by Dr Veerabhadra Rao (Retina Fellow) while examining a patient at the Vision Centre. The attachment described was built in the instruments maintenance laboratory, with Dr Rao giving the necessary suggestions for improvement at various stages of development.



**Figure 1. Fundus photograph taken with a digital camera**

Veerabhadra Rao

**Knowledge and attitude of general practitioners towards diabetic retinopathy practice in South India**

**Rajiv Raman, Pradeep G Paul, Padmajakumari R, Tarun Sharma**

Diabetic Retinopathy Project, Sankara Nethralaya, 18 College Road, Nungambakkam, Chennai, 600006, India.

Email: [tarusharma@eth.net](mailto:tarusharma@eth.net)

**Introduction:** General practitioners (GPs) are important members of the diabetic care network. Awareness levels of general practitioners are vital in planning strategies to prevent diabetic blindness. The present study was done to assess the knowledge, attitudes and practices (KAP) of urban GPs regarding the screening and management of diabetic retinopathy.

**Research design and methods:** A questionnaire was designed to assess the GPs' KAP in handling diabetic retinopathy. Questions related to referrals, direct ophthalmoscopy, and barriers to diabetic retinopathy screening. Urban GPs from Chennai were contacted through telephonic interview. GPs' telephone numbers were traced from the Yellow Pages and a random digit dialing strategy was used. Telephonic survey was done for 450 telephone numbers of GPs.

**Results:** Of the 450 telephone numbers of GPs that were dialled, only 187(41.6 per cent) responded to the questionnaire. 52 per cent of the GPs declined to answer questions. Among those who responded to the call, only 85 per cent (n =159) completed the tele-survey completely. Most of the GPs could not be contacted in the morning, as they were busy with their practice. Among those who successfully completed the survey, 46.6 per cent (n= 74) of the

*Continues over page* ➤

GPs responded to the tele-survey after they were called more than five times. 33.4 per cent (n = 53) of the general practitioners responded after three to five calls and the remaining 20 per cent responded immediately.

31.3 per cent (n=50) feel that diabetics should undergo an eye examination every six months and 53.3 per cent (n=85) feel that diabetics should undergo eye examination every year. 15.4 per cent felt that eye examination every two years is sufficient for diabetics. Ophthalmoscopy was done by 1.3 per cent (2/159) of the GPs. Of the two, one GP performs ophthalmoscopy with dilation while the other performs it without dilation. The reason stated for not dilating was lack of time. Almost all GPs said that they would refer a patient with diabetes to an ophthalmologist. 84 per cent of the practicing physicians were aware of laser photocoagulation as a treatment modality for diabetic retinopathy.

54 per cent of GPs were aware of annual dilated eye examination referral guidelines for diabetics. Regarding attitudes for screening for diabetic retinopathy, only 1.3 per cent of GPs were using direct ophthalmoscope. Among them only 50 per cent were practicing dilated direct ophthalmoscopy. Barriers for doing diabetic retinopathy screening by general practitioners were lack of time, lack of ophthalmoscopes and lack of training.

**Discussion:** This study shows the need for training GPs about diabetic retinopathy and its detection with direct ophthalmoscope. Barriers for dilated eye examination, as perceived by GPs, need to be addressed. McCarty et al.<sup>1</sup> reported that lack of dilating drops in the practice, lack of confidence in detecting changes, concern about time taken and fear of precipitation of angle-closure glaucoma with their patients were some of the barriers expressed by GPs. Knowledge of the guidelines is another important factor to consider. Residency programmes should focus on providing more exposure to ophthalmoscopy practice among GPs, compared to the current low levels of exposure of only a few hours.

#### References

1. McCarty et al. Management of diabetic retinopathy by general practitioners in Victoria. *Clin Exper Ophthalmol* 1987, 29:12-16.

## Getting over the histopathology barrier

**Michael Ekuoba Gyasi** and **Oscar Debrah**

Bawku Presbyterian Hospital, Bawku, Upper East Region, Ghana.

In many developing countries, specialised laboratory services are simply non-existent. Where they exist, they are usually limited to large hospitals. The distance and the cost of accessing such specialised services, place enormous barriers to remote eye care facilities and the patients they serve. In Ghana, getting histopathology tests done could take as long as three months. In our case, the patient has to send it to the nearest facility, located some 600 kilometres away. Such a situation meant that most ophthalmic specimens simply never saw the microscope at all. That is why we felt relieved when a global mail was sent by the Vice President of our Ophthalmological Society, introducing members to a free histopathology service at the Royal Hallamshire Hospital in the UK.

Through such collaboration, we now have a free and reliable ophthalmic histopathology service with results delivered within a few days through email. Packaging materials and guidelines are provided free, with only outward postage paid by the beneficiary institution.

Visiting the centre recently, however, I realised that only a fraction of clinics in Africa have taken advantage of this facility, despite the obvious benefits derived from histopathologic evaluations.

This International Ophthalmic Histopathology Service, is accessible to all developing countries. The centre can be contacted through the following address:

Dr Hardeep Mudhar, Ophthalmic Pathology, Department of Histopathology, E-Floor, Royal Hallamshire Hospital, Glossop Road, Sheffield S10 2JF, UK. Tel: (+44) 0114 2268967.

Email: [hardeep@mudharh.fsnet.co.uk](mailto:hardeep@mudharh.fsnet.co.uk)

## The importance of shielding the eye in referrals of ocular injuries

**Tontu Zik**

Ophthalmic Clinical Officer, Mbingo Baptist Hospital Eye Department, Cameroon.

Email: [MBHCameroon@aol.com](mailto:MBHCameroon@aol.com)

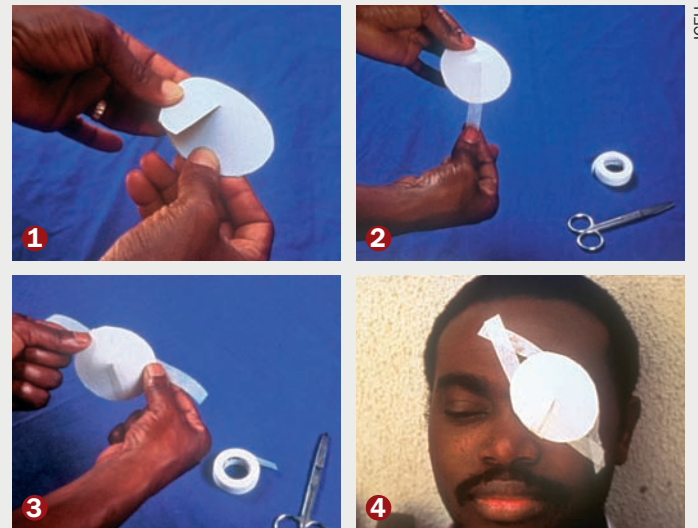
Ocular injuries are common in the northwest province of Cameroon. Here, the majority of the people are farmers. In 2004, 31 patients with ocular injuries were seen in Mbingo Baptist Hospital Eye Department. As of November 2005, 17 patients have been seen. Injuries to the lids are not included. Causes of these injuries include tree branches and leaves, lacerations from knives and cutlasses, pellets from locally made guns used during traditional ceremonies, stone fragments injuring the eye when cracking stones without wearing protective spectacles, sticks and stones when children play.

The majority of people live far away from an eye hospital. Some villages require eight hours of trekking to reach a motorable road to the hospital. The visual prognosis after management of an ocular injury will not only depend on the extent and location of the injury, but also on what happens during transportation to the hospital. The majority of our roads are rough, untarred and dusty. These expose the eye, especially an open injury, to further trauma and foreign bodies. Further injury to the eye during referral could be reduced by the use of an eye shield.

Making an eye shield is easy and inexpensive. It can be made from cardboard or firm paper. Health centres and health posts found in the villages readily have this, for example, from medication boxes. Where available, used x-ray film can also be used.

Our community outreach programme is in partnership with the community-based rehabilitation programme of the Cameroon Baptist Convention Health board, sponsored by Christoffel-Blindenmission (CBM). Their field workers and volunteers see and refer eye patients in the community. Every year, refresher courses are organised, where they are taught, amongst other things, how to make an eye shield.

**Figure 1. How to make an eye shield**



ICEH

## 2006 themes

The themes planned for 2006 include:

**Outreach: beyond the clinic** (June 2006)

**Finding the cataract patient** (September 2006)

**Glaucoma** (December 2006).

Readers are invited to submit 500 word submissions on any of these themes, or any other topic relevant to community eye health. If you want your submission to be considered for a particular theme, please ensure that I receive it at least one month before the publication date.

Victoria Francis, Editor, *Community Eye Health Journal*



## NOTICES

# Some findings from the reader survey



**Victoria Francis**  
Editor, *Community Eye Health Journal*

The 2004/2005 Reader Survey for the *Community Eye Health Journal (CEHJ)* provided us with a wealth of information about our readers, their opinions about the journal's usefulness and relevance, and suggestions for improvement.

comes after four months. The results are an eye opener. We have encouraged others to this too. You can use the results to audit your work. It's great!  
**Ophthalmic nurse. Zimbabwe**

We now have a better understanding of patients' difficulties. We try to recognise their needs and try to communicate and cooperate with them at a deeper level. We give the visually impaired more time to explain themselves and we take time to explain to them in greater detail.  
**Nurse. Cameroon**

Forty one per cent of readers report using the journal for teaching a wide range of audiences in different settings, and describe how they translate the articles into other languages and different media for presentations.

I make photocopies of different articles and distribute among the students when I deliver any subject. I also... photocopy onto transparent sheets for OHP.  
**Ophthalmologist. Bangladesh**

Showing community health workers photos of eye diseases so that they can know which cases have to be referred to the rural health centres and which ones have to go to hospital.  
**Ophthalmic assistant. Zambia**

We laminated the different pictures of retina to use on explaining to patients the proliferative changes in Diabetic and Hypertensive Pathology.  
**Ophthalmic nurse. South Africa**

During outreach we use the journal to teach the community; with pictures the community is able to understand. In the clinic the patients also understand more with the pictures and the message is carried across.  
**Ophthalmologist. Kenya**

## How can CEHJ be further improved?

In response to the sentence completion: "The journal could be improved if..." , respondents suggested improving:

- the quality of the journal, including attention to different themes, and continued improvement in the format and use of graphics
- the reach/distribution of the journal, including other translations
- the usability of journal material by expanding into a wider range of media, such as CD-ROM, composite print versions, other teaching materials such as posters, videos, and distance learning courses with accreditation
- information about courses, jobs and training.

Readers' suggestions have been presented at editorial committee meetings and provide a valuable resource to the editorial team. Already many of your suggestions have been acted upon. Many thanks to all readers who took the time to return the questionnaires! A full report of the reader survey will be available on the ICEH website in May 2006.

## What do readers like about CEHJ?

Ninety seven per cent of readers report finding the journal very useful or useful. The top four types of material described as "very useful" were ranked as: articles on the theme for the issue, Evidence-based Eye Care Series, the Technology Series and original research.

The following quotes reflect something of the diversity of comments about what readers like about CEHJ.

*It helps me to upgrade myself. It helps me to understand certain eye conditions well, and their management. It helps me to know what is going on in the other countries ...and the interventions they are taking.*

**Ophthalmic nurse. Ghana**

*The study of ophthalmic assistants course helped me to get a job, but study of Community Eye Health Journal improved my knowledge and my responsibility in the field of prevention of blindness.*

**Ophthalmic assistant. India**

*...it is teaching by itself without teachers...*

**Teacher. Ethiopia**

*Very easy to read and it is like a mirror to us, we see ourselves in the journal hence it increases my confidence and gives me hope to continue to work successfully.*

**Ophthalmologist. Ghana**

*...it encourages me to reach out to the low income-earners and less privileged in the society.*

**Optometrist. Nigeria**

*...it is sent to people living in developing countries free of charge. For this reason many poor people like some of the us are able to have it.*

**Optical technician. Cameroon**

## Does CEHJ change the way readers practice eye care?

In response to the question "Has any article in the journal helped you to change your practice?" 72 per cent (n = 1,235) answered 'yes', with 84 per cent of these (n = 1,040) providing descriptions of how their knowledge, attitudes and practice have changed as a result of reading the journal, for example:

*Some of the articles have 'touched' me in several ways. They teach you to evaluate the community as a whole, not just the individual. Also to do a better analysis of the situations. They also give examples that sometimes can be applied in your region.*

**Ophthalmologist. Colombia**

*I have now tended to make small corneo-scleral incisions during cataract surgery. I have found it better than the previous large incisions which caused complications like iris prolapse.*

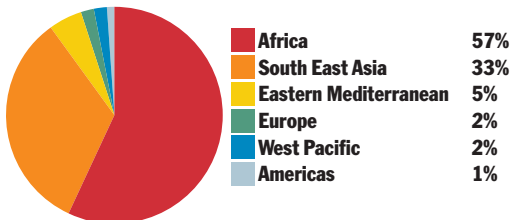
**Cataract surgeon. Uganda**

*After reading the article on the importance of monitoring cataract surgical outcomes, we introduced cataract cards and monitor the vision of each cataract-operated patients on day one, two weeks and six weeks. If the patient can, he or she*

## Who responded?

1,704 readers from 84 countries returned the questionnaire within the required time. Figure 1 provides a picture of the regional breakdown of respondents and highlights the fact that the greatest proportion of returns came from Africa, which also provided the best response rate at 13 per cent.

Figure 1. Regions represented in the survey



## Who are our readers?

### Jobs and level of service provision

Sixty per cent of our readers have specialist ophthalmic training, of which 23 per cent are ophthalmologists and 37 per cent are mid-level eye workers. This mid-level group has increased by 17 per cent since the last survey in 1997.

Figure 2. Range of professions

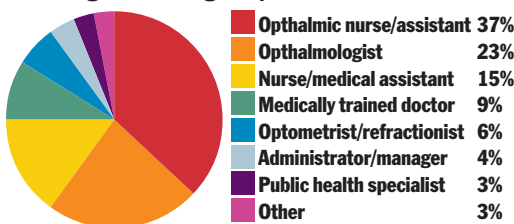
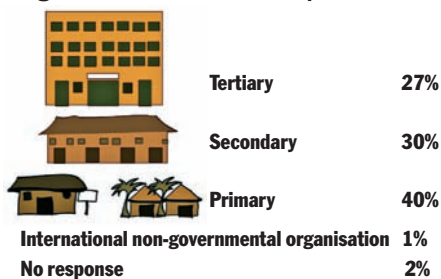


Figure 3. Levels at which respondents work



### Languages used by respondents

Eighty three per cent of respondents include English in their list of working languages. Of these, 25 per cent use English exclusively, while 58 per cent use it with one or more other local languages – 165 different languages are mentioned, the most common of which are Kiswahili, Hausa, Hindi, Kannada, Amharic, French, Gujarati, Ibo, Malayalam, Urdu and Yoruba.

### Access to the internet

There has been a notable change since the 1997 survey, when just over 20 per cent of the readership had access to the internet, compared to the overall total of 51 per cent in the recent survey. Of those who do have access, 24.3 per cent rely on internet cafés.

## NOTICES

### Erratum

We apologise for a spelling error in the EXCHANGE section of Volume 18 Issue 56. The author of the article "A low-cost, slit lamp-based video-photodocumentation system" is **Syed Amjad Rizvi**, not Syed Amjad Nizvi as published in the paper version. – Editor

### Obituary

We have been very sad to hear of the untimely death of Dr Vijay Mehra. He was a member of the first class of diploma students at the International Centre for Eye Health in 1981, just after Professor Barrie Jones had started the new department. He was the first alumnus to become active in population-based research and he was responsible, in collaboration with Dr Darwin Minassian and Dr Angela Reidy, for some landmark observations on cataract aetiology and incidence. We send our deep sympathy to his family and everyone in India who was associated with Dr Vijay Mehra.

– Professor Gordon J Johnson, Director of ICEH 1986-2002

### Courses and conferences

#### 6th International Glaucoma Symposium (I.G.S)

March 28-31, 2007. **Venue:** Athens, Greece. **Information:** Symposium Organisers, Kenes International – Global Congress Organizers and Association Management Services, 17 Rue du Cendrier, PO Box 1726, CH-1211 Geneva 1, Switzerland. Tel: (+41) 22 908 0488, Fax: (+41) 22 732 2850. Email: [glaucoma@kenes.com](mailto:glaucoma@kenes.com) Website: [www.kenes.com/glaucoma](http://www.kenes.com/glaucoma)

#### Planning for VISION 2020 short course

July 3-7, 2006. **Venue:** London School of Hygiene and Tropical Medicine, London. **Cost:** £630. **Information:** [Adrienne.Burrough@Lshhtm.ac.uk](mailto:Adrienne.Burrough@Lshhtm.ac.uk) or [shortcourses@lshhtm.ac.uk](http://shortcourses@lshhtm.ac.uk)

#### Certificate course in Community Eye Health

October 16 - December 8, 2006. **Venue:** Kilimanjaro Centre for Community Ophthalmology. **Course aims and objectives:** To equip eye health professionals with the skills necessary to develop, implement, and manage a VISION 2020 programme. The eight-week course will focus on disease control, planning, human resource development, management, bridging strategies, and budgeting. The course is suitable for ophthalmologists, project managers, or other eye care professionals who are responsible for developing and implementing district VISION 2020 plans. **Information and admission procedures:** Dr Paul Courtright – Email: [pcourtright@kcco.net](mailto:pcourtright@kcco.net)

### New resources available

**Marsden J (editor). Ophthalmic Care.** A new comprehensive textbook written by an international panel of ophthalmic nurses and other contributors. Wiley, 2006. Available from the International Resource Centre, ICEH. Discount price: UK £25 plus post and packaging (for developing countries only). Enquiries – Email: [sue.stevens@Lshhtm.ac.uk](mailto:sue.stevens@Lshhtm.ac.uk)

#### Kanski J J. Clinical Ophthalmology – a synopsis

Butterworth Heinemann, 2004. Available from the International Resource Centre, ICEH. Discount price: UK £30 plus post and packaging (for developing countries only). Enquiries – Email: [sue.stevens@Lshhtm.ac.uk](mailto:sue.stevens@Lshhtm.ac.uk)

### Useful resources: Back of the eye

#### Johnston R L. Retina, Vitreous & Choroid Clinical Procedures

Butterworth Heinemann 1995. Available from Waterstones at £36.

#### Allen C et al. Retina – Colour Atlas & Synopsis of Clinical Ophthalmology

McGraw Hill Higher Education, 2003. Available from Waterstones at £36.

#### Clarke H B. Retinal Detachment: The Essentials of Management

Butterworth Heinemann, 1998. Available from Waterstones at £42.

#### Freeman W R (editor). Practical Atlas of Retinal Disease and Therapy

Lippincott, Williams & Wilkins, 1997. Available from Waterstones at £26.

#### Aldiss B. Detached Retina

Syracuse University Press 1995. Available from Waterstones at £10.

#### Wu Gloria. Retina: The Fundamentals

Saunders (W B) 1995. Available from Waterstones at £33.

#### Packer A J. Manual of Retinal Surgery

Butterworth Heinemann, 2000. Available from Waterstones at £31.

  
**LONDON SCHOOL OF HYGIENE & TROPICAL MEDICINE**

  
**INTERNATIONAL CENTRE FOR EYE HEALTH**

## MSc Community Eye Health

**Dates: 25th September 2006 - 14th September 2007**  
**Cost: £13,750 (Overseas) or £4,370 (Home)**  
**Venue: The London School of Hygiene & Tropical Medicine**

The MSc in Community Eye Health is designed to equip eye care professionals and planners with the knowledge and skills to reduce blindness and visual disability. Training in community eye health extends the training in clinical ophthalmology applied to individual patients, to a consideration of the eye health of whole populations - how these can be assessed, resourced and evaluated.

The course is designed in keeping with the aims, priorities and strategies of VISION 2020. VISION 2020 is a World Health Organisation programme designed to eliminate avoidable and treatable blindness, globally, by 2020. Applicants are expected to be health care professionals involved in eye care and have relevant work experience.

Course duration is one year (full-time) but it is available on a part-time basis over two years.

**Application forms are available from the Registry, 50 Bedford Square, London WC1B 3DP, UK.**  
**Telephone: +44 (0)20 7299 4646 fax: +44(0)20 7323 0638,**  
**e-mail: [registry@lshhtm.ac.uk](mailto:registry@lshhtm.ac.uk) or [MSCCEH@lshhtm.ac.uk](mailto:MSCCEH@lshhtm.ac.uk)**  
**Website: [www.lshhtm.ac.uk/prospectus/masters/msceh.html](http://www.lshhtm.ac.uk/prospectus/masters/msceh.html)**

**Please quote ref: JCEH.**

#### Liesegang T J et al. Retina and Vitreous – Section 12 – Basic Clinical Science Course

Updated annually. Produced by the American Academy of Ophthalmology. Enquiries – Email: [wovait@aaoo.org](mailto:wovait@aaoo.org)

#### Advances in Vitreo-Retinal Disease Management CD

Aravind, 2002. Produced by LAICO.

Enquiries – Email: [communications@aravind.org](mailto:communications@aravind.org)

#### Retinopathy of Prematurity Study

This technical paper reports the results of a retrospective study of ROP at the National Institute of Paediatric Care, Vietnam. The study is part of the first diagnosis, prevention and treatment project in the country. Available from ORBIS International.

#### Retinopathy of Prematurity Screening

A 28-minute instructional video for ophthalmologists presenting a model developed by the L V Prasad Eye Institute in India for the screening, diagnosis and management of ROP. Available from LVPEI.

#### Community Eye Health Journal back issues

Volume 9, Issue 20, 1996 – Diabetes and Diabetic Retinopathy

Volume 10, Issue 22, 1997 – Retinopathy of Prematurity

Volume 16, Issue 46, 2003 – The Retina

### Suppliers

**Waterstones**, 71-74 North Street, Brighton, East Sussex, BN1 1ZA, UK.

Email: [manager@brighton.waterstones.co.uk](mailto:manager@brighton.waterstones.co.uk)

**American Academy of Ophthalmology**, 655 Beach Street, Box 7424,

San Francisco, CA 94120-7424, USA. Email: [wovait@aaoo.org](mailto:wovait@aaoo.org)

**L V Prasad Eye Institute**, Central Audio-Visual Unit, L V Prasad Marg,

Hyderabad – 500034, Andhra Pradesh, India. Email: [mshoba@lvpei.org](mailto:mshoba@lvpei.org)

**ORBIS International**, 520

8th Avenue, 11th Floor,

New York, NY 10018, USA.

Email: [dcharles@ny.orbis.org](mailto:dcharles@ny.orbis.org)

**LAICO – Aravind Eye Care**

**Services**, 1 Anna Nagar,

Madurai, 625 020, Tamil

Nadu, India. Email:

[communications@aravind.org](mailto:communications@aravind.org)

### Article competition

Thank you to readers who submitted an article for the article competition. The final selection of articles will take place at the next editorial meeting in April.

### Next issue



The next issue of the *Community Eye Health Journal* will be on the theme **Outreach: beyond the clinic**

Victoria Francis

## Community Eye Health

# JOURNAL

Supported by



**Christian Blind Mission International**

**sightsavers INTERNATIONAL**


**Sightsavers International**



**ORBIS**



**Dark & Light Blind Care**



**Conrad N. Hilton Foundation**

**TIJSSSEN FOUNDATION**

**Tijssen Foundation**

**The Fulmer Charitable Trust**