VOLUME 31 • NUMBER 103 • 2018

Community Eye Health Journal

Early detection of eye emergencies is essential – whether in the community or in hospital. TANZANIA
WWW.ABBOTT.COM

Managing and preparing for eye emergencies

John Buchan
Consultant Ophthalmologist: International Centre for Eye Health, London School of Hygiene and Tropical Medicine, London, UK.

Seema Verma
Consultant Ophthalmologist and President of the British Emergency Eye Care Society, London, UK.

Eye emergencies can have devastating consequences. We should do everything in our power to ensure that patients' sight – and lives – can be saved.

Whilst most eye problems progress gradually and can be dealt with in routine clinical practice, there are times when action can save someone's sight, or even their life.

This issue of the *Community Eye Health Journal* looks at some of the conditions for which emergency intervention is essential and where delay, of even a few hours, can have devastating consequences.

Anyone working in eye care can learn to identify an eye emergency. Some emergencies, such as retinal detachment (p. 63), must be attended to by a specialist surgeon. In this case, the role of the front-line eye health worker is to identify patients who need urgent treatment and refer them. Other patients with acute conditions, such as compression of the optic nerve, must be treated immediately. In this case, front-line members of the eye care team should be prepared to perform a sight-saving lateral canthotomy (p. 62).

In each example, the key to saving sight is preparation, whether that is developing an effective referral pathway for retinal detachment, ensuring that access to acetazolamide for acute angle-closure glaucoma is possible outside of normal working hours (p. 64), or practising setting up for an anterior vitrectomy (p. 65). If we are not ready and waiting for these emergencies, we will miss the opportunity to prevent blindness or save someone's life.

About this issue

Eye emergencies can lead to blindness, and even death, in a very short period of time. Early and appropriate intervention – sometimes within a matter of hours – is crucial.

We have designed this issue to help you plan and prepare for the most common eye emergencies. Learn to recognise each emergency, use our checklists to ensure you and your team have everything you need, and practise, practise, practise!

– Elmien Wolvaardt and David Yorston

Contents

Managing emergencies: lessons from aviation

David Yorston
Consultant Ophthalmologist: Tennent Institute of Ophthalmology, Gartnavel Hospital, Glasgow, Scotland, UK.

Mike Duncalfe
Flight Operations Manager: Mission Aviation Fellowship, Papua New Guinea.

There is no need to be surprised by an eye emergency – preparation and practice make all the difference.

Many will remember the remarkable pictures and story of the US Airways passenger jet that lost all power and landed on the Hudson river, in the middle of New York, without loss of life or serious injuries. Although emergencies are rare in the day to day routine of modern air transport, the aviation industry still devotes a great deal of time and money to learning how to avoid accidents and emergencies, and also how to handle them when they happen.

Much has been written and said about the parallels and differences between aviation and medicine. Although an eye clinic is very different from an aircraft, there are things we can learn from the air transport industry's approach to managing emergencies.

Airlines and aircraft manufacturers devote considerable time and resources to planning for emergencies. As flying in a commercial aircraft is now the safest way to travel per passenger mile, aviation emergencies are increasingly rare. Despite this, preparedness for emergencies continues to be a priority for the industry. Although the ophthalmic emergencies discussed in

Community Eye Health Journal
VOLUME 31 • NUMBER 103 • 2018

International Centre for Eye Health

VISION 2020 THE RIGHT TO SIGHT

LONDON SCHOOL of HYGIENE &TROPICAL MEDICINE

IAPB

CEHJ online
Visit the *Community Eye Health Journal* online. All back issues are available as HTML and PDF.
Visit: www.cehjournal.org

Online edition and newsletter
web@cehjournal.org

Please support us
We rely on donations / subscriptions from charities and generous individuals to carry out our work. We need your help.
Subscriptions in high-income countries cost UK £100 per year. Contact Anita Shah admin@cehjournal.org or visit our website: www.cehjournal.org/donate

Subscriptions
Readers in low- and middle-income countries receive the journal free of charge. Send your name, occupation, and postal address to the address below. French, Spanish, and Chinese editions are available. To subscribe online, visit www.cehjournal.org/subscribe

this issue of the journal are all, individually, relatively uncommon, all eye workers will at some point encounter patients in need of emergency treatment. The outcomes for these patients – whether or not they regain their sight – will depend on the time and effort that eye health workers put in preparing for such emergencies.

Teamwork

The aviation industry's culture of preparedness is based on crew resource management (CRM).[1] In summary, CRM is an approach that requires the whole team to be prepared, not just the pilot. If an emergency occurs, every member of the crew has a role in dealing with it, and each member of the crew carries that responsibility. In the setting of an eye clinic, this means that management of an emergency is not just the job of the ophthalmologist, but of the whole team working together. For example, if a patient attends with a severe corneal ulcer, the clinic receptionist should recognise that this is a serious problem, and ensure that they are seen promptly. The eye nurse identifies that this is probably a bad corneal ulcer, and ensures that the equipment needed to take a specimen is ready and available. The pharmacist can start to prepare high potency eye drops so that treatment can be started as soon as the diagnosis is confirmed. The ophthalmologist listens to the input of the nurses and other eye clinic workers, so that she or he is ready to take the specimens and start the treatment.

Standard operating procedures

Aviation also relies on having standard operating procedures in place. These are written guidelines and protocols that give details about what action should be taken in the event of an emergency. Although you may think you know how to manage acute glaucoma, having it written down, and accessible, minimises the risk of making a mistake or forgetting something. All eye clinics should have written protocols for eye emergencies. These should be written for the clinic, and give specific instructions, e.g., a list of the equipment needed to take a specimen from an infected corneal ulcer, or a description of how to prepare the correct dose of antibiotics for intravitreal injection. All eye clinic personnel should have access to the protocols at all times.

Planning and preparation helped to avoid loss of life when US Airways Flight 1549 crash-landed on the Hudson river, New York, in 2009. USA

Preparation and practice

Air crews practise and simulate emergencies. Pilots have access to complex and expensive simulators that allow them to experience what it is like to fly an aircraft after an engine failure. When the real event occurs, their training and experience help them to make the correct decisions. In ophthalmology we don't need complicated simulators to prepare for emergencies. Teams can practise preparing intravitreal antibiotics with a few syringes. The theatre team can prepare for the management of vitreous loss by keeping a vitreous cutter aside as a practice instrument and carrying out regular drills to ensure that all the theatre nurses know how to assemble and connect it.

Everyone needs to devote time and energy to planning and preparing for emergencies. The training and preparation has to extend to the whole eye care team so that everyone understands their responsibilities, and, with the aid of standard guidelines, knows exactly what they need to do when confronted by a patient with an ophthalmic emergency.

Further reading

1 Crew resource management (CRM) online tutorial and resources **www.crewresourcemanagement.net**

Address for subscriptions
Anita Shah, International Centre for Eye Health, London School of Hygiene and Tropical Medicine, Keppel Street, London WC1E 7HT, UK.
Tel +44 (0)207 958 8336
Email admin@cehjournal.org

Correspondence articles
We accept submissions of 800 words about readers' experiences.
Contact Anita Shah:
correspondence@cehjournal.org

Published by the International Centre for Eye Health, London School of Hygiene & Tropical Medicine.

ISSN 0953-6833.

The *Community Eye Health Journal* is supported by:

cbm together we can do more
Conrad N. Hilton Foundation
Sightsavers
seva.org
iTi International Trachoma Initiative
The Queen Elizabeth Diamond Jubilee Trust
MSD
The Fred Hollows Foundation
orbis
Tijssen Foundation

Emergency management: orbital cellulitis

Fatima Kyari
Consultant Ophthalmologist
Medical Education Coordinator,
Baze University,
Abuja, Nigeria.

Orbital cellulitis is an infection of the deep tissues of the orbit. It is life-threatening, as infection can easily spread into the brain.

JAMES GARRITY, WWW.MSDMANUALS.COM

Orbital cellulitis. Clinical signs include proptosis, peri-orbital skin erythema, lid oedema and conjunctival chemosis.

Orbital cellulitis is usually the result of infection that has originated in the paranasal sinuses and spread to the orbit. It may arise due to the spread of minor infections of the eyelid, the face and the lacrimal sac or, rarely, from endophthalmitis. Orbital cellulitis can also occur when infections in other parts of the body spread through the bloodstream (haematogenous spread). The organisms most commonly isolated from orbital infections are *Staphylococcus spp.*, *Streptococcus spp.* and *Haemophilus spp*.

If treatment is inadequate and/or delayed, vision loss, cavernous sinus thrombosis, intracranial abscess, meningitis, osteomyelitis and even death can occur within a short time.

Orbital cellulitis is an emergency and admission and in-patient management must be instituted immediately.

Symptoms

Patients may present with pain, fever (especially in children), frontal headache, swelling of the eye or double vision. There is often a history of upper respiratory tract infection.

Signs

Clinical signs include:

- Proptosis (forward displacement of the eye)
- Peri-orbital skin erythema (redness) and lid oedema
- Conjunctival chemosis (inflammation and swelling of the conjunctiva).
- Limited eye movement.

Due to the proptosis, there may be exposure keratopathy with corneal ulceration.

The optic nerve head may be swollen.

Visual acuity may be decreased. Vision loss may be due to corneal ulceration or ischaemic necrosis of the optic nerve due to mechanical pressure. However, vision loss is often temporary and improves with treatment.

The patient is usually unwell, as there may be associated sepsis, with fever, nausea and vomiting, and even cognitive impairment and confusion.

Remedies and immediate management

1. Immediately begin systemic (intravenous) antibiotic treatment using broad-spectrum antibiotics that are effective against most Gram positive and Gram negative bacteria. A combination of **third-generation cephalosporin** and **flucloxacillin** is recommended.
2. Make the patient comfortable: relieve pain, treat fever and prevent/treat vomiting and dehydration.
3. Investigate the primary source of infection if possible.

The single most important imaging investigation in orbital cellulitis with suspected orbital abscess is a CT scan, as this would aid in the detection and demarcation of the abscess and assessment of the sinuses. However, this may not be possible in resource-poor environments. Ocular ultrasonography is also useful in cases of orbital abscess, and plain sinus X-rays may show air-fluid level in the sinuses.

Referral and/or follow-up

Surgical drainage of orbital or subperiosteal abscess is indicated in some cases of orbital cellulitis. These patients should be referred urgently for surgery as delayed intervention is associated with poor results.

Careful monitoring of patients is essential, as they may need oral antibiotics after the initial intravenous antibiotics. Children with vision loss should be followed up to measure their visual acuity and assess whether they need further treatment.

Be prepared

- Ensure that everyone with eye care responsibilities knows the signs of orbital cellulitis: it is an emergency that can result in blindness and death
- Create a poster or protocol that lists the clinical signs and what to do. You can download the images in this issue from **www.flickr.com/photos/communityeyehealth/**
- Put together an orbital cellulitis pack containing an IV bag, antibiotics and a set of instructions for preparing the antibiotics. Check regularly to ensure that the medicines are in date
- Practise preparing the IV bag and antibiotics.

Further reading

1 Chaudhry IA, Al-Rashed W, Arat YO. The Hot Orbit: Orbital Cellulitis. Middle East African Journal of Ophthalmology. 2012;19(1):34-42. doi:10.4103/0974-9233.92114.

2 Gonzalez MO, Durairaj VD. Understanding Pediatric Bacterial Preseptal and Orbital Cellulitis. Middle East African Journal of Ophthalmology. 2010;17(2):134-137. doi:10.4103/0974-9233.63074.

3 Tsirouki T, Dastiridou AI, Ibánez Flores N, Cerpa JC, Moschos MM, Brazitikos P, Androudi S. Orbital cellulitis. Surv Ophthalmol. 2018 Jul - Aug;63(4):534-553. doi: 10.1016/j.survophthal.2017.12.001. Epub 2017 Dec 15.

Emergency management: ophthalmia neonatorum

Ophthalmia neonatorum can cause corneal perforation and intraocular infection.

Bolutife Olusanya
Senior Lecturer and Consultant Paediatric Ophthalmologist: Department of Ophthalmology, College of Medicine, University of Ibadan, Ibadan, Nigeria.

Aderonke Baiyeroju
Professor and Head of Paediatric Ophthalmology Unit: University of Ibadan, Department of Ophthalmology, College of Medicine, University of Ibadan, Ibadan, Nigeria.

Conjunctivitis in a newborn baby is known as ophthalmia neonatorum (ON). It is an acute emergency and requires immediate treatment and referral because of the significant risk of corneal perforation and intraocular infection that can very quickly lead to blindness.[1]

ON is most common in the babies of mothers infected with the sexually transmitted diseases *Chlamydia trachomatis or Neisseria gonorrhoeae*. Babies' eyes become contaminated during birth.

Presentation and diagnosis

Ophthalmia neonatorum usually develops between 2 and 14 days after birth. Babies present with redness and swelling of the eyelids, 'sticky eyes' and/or discharge from one or both eyes.[2]

Treatment and referral

Ideally, a swab of the discharge should be obtained in order to determine which organism is responsible. In the absence of easy access to laboratory diagnosis, the World Health Organization recommends that babies should be treated for both gonococcal and chlamydial infections (see panel, right).

For **gonococcal ON**, the recommended treatment is a single dose of intramuscular ceftriaxone injection (50 mg/kg of bodyweight, maximum 125 mg). Alternatives include kanamycin and spectinomycin.[2]

For **chlamydial ON**, the recommendation is 50 mg/kg of erythromycin syrup per day, divided into 4 doses, for 14 days.[2]

Regardless of which organism caused the infection, frequent saline irrigation and cleaning of the eyes is necessary to remove the eye discharge. Topical antibiotics such as erythromycin ointment may be used as an additional therapy. Urgent referral is indicated if there is no improvement within 24–48 hours, or there are signs of sepsis, such as high/low temperature, no interest in feeding, difficulty breathing, vomiting, or if the baby is floppy/unresponsive. In addition, it is important to treat the mother and her partner.

Prevention

Ophthalmia neonatorum can be prevented before birth by treating maternal infection due to *Chlamydia trachomatis* or *Neisseria gonorrhoea*.

After birth, the infection can be prevented by cleaning the baby's eyes using normal saline and applying an antibiotic eye ointment, such as tetracycline or erythromycin.

Avoid the use of silver nitrate, if possible, as it is associated with chemical conjunctivitis.

TS OLULEYE, UNIVERSITY COLLEGE HOSPITAL, IBADAN, NIGERIA

Profuse purulent discharge in a child with ophthalmia neonatorum. NIGERIA

Types of ophthalmia neonatorum

Chlamydial conjunctivitis is the most common type of ON.[1] It usually presents within 5–14 days of life with redness of the eyes and mucopurulent eye discharge. Most cases are mild to moderate and are self-limited. Eyelid and conjunctival swelling may occur in severe cases. Children with very severe disease may have associated respiratory tract infection.

Gonococcal ON is less common than chlamydial conjunctivitis but is more severe,[1] so parents are more likely to bring their babies to hospital. It becomes noticeable 2–5 days after birth with copious purulent eye discharge (Figure 1) and severe redness and swelling of the conjunctiva. The eyelids are often very swollen. If untreated, or inadequately treated, it can very quickly result in corneal haziness and perforation, causing blindness. Babies with very severe disease may have systemic complications such as septicaemia and meningitis.

DU TOIT N AND VAN ZYL L (2013)

Figure 1 Purulent gonococcal conjuctivitis

Other conditions that may present with features similar to ON include birth trauma, orbital cellulitis, dacryocystitis and congenital glaucoma. Chemical conjunctivitis may develop as a mild conjunctivitis in a newborn with mucoid eye discharge, redness of the eyes and mild swelling of the eyelids, resolving spontaneously within 48 hours.

References

1 Kapoor VS, Whyte R, Vedula SS. Interventions for preventing ophthalmia neonatorum. Cochrane Database of Systematic Reviews 2016; Issue 9. Art. No.: CD001862. DOI: 10.1002/14651858.CD001862.pub3.

2 World Health Organization. Guidelines for the Management of Sexually Transmitted Infections. February 2004. **http://apps.who.int/medicinedocs/en/d/Jh2942e/3.6.html#Jh2942e.3.6/** (accessed 18 September 2018).

Emergency management: optic nerve compression

Colin Cook
Professor and head of the Division of Ophthalmology: University of Cape Town, Groote Schuur Hospital, Cape Town South Africa.

Increased orbital pressure compresses the optic nerve, which can lead to irreversible vision loss in a matter of hours.

The orbit is a bony box containing the eye and surrounding soft tissues, including part of the optic nerve. A significant increase in the pressure inside the orbit can reduce orbital blood supply and compress the optic nerve, causing damage. In acute cases, irreversible visual loss can occur after 90–120 minutes, unless the pressure is reduced and the blood supply restored.[1]

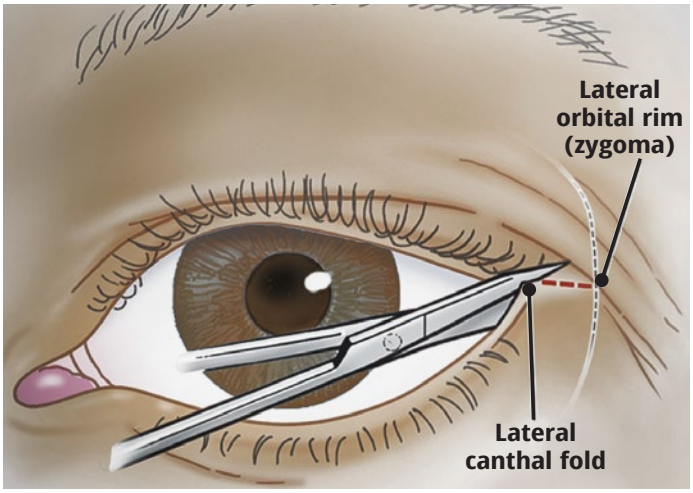

ADAPTED FROM REICHMAN EF: EMERGENCY MEDICINE PROCEDURES 2ND EDITION. WWW.ACCESSEMERGENCYMEDICINE.COM

Figure 1 Performing a surgical canthotomy will relieve pressure on the optic nerve. This can save the person's sight if done in time.

What are the symptoms and signs of optic nerve compression?

In addition to a possible history of trauma, surgery or proptosis (forward displacement of the eye), the patient with optic nerve compression can present with the following:

- Pain
- Visual complaints (e.g., blurred or double vision and peripheral, slow, intermittent or sudden visual loss)
- Unexplained nausea and vomiting.

Clinical signs of optic nerve compression include:

- Decreased visual acuity
- Resistance to retropulsion of the eye (a 'tense' eye)
- Increased intraocular pressure
- Relative afferent pupillary defect[2]
- Inability to read colour vision plates (due to colour blindness).

Causes of orbital compression

Soft tissue swelling. This can be due to tumours, trauma, infections or inflammation (e.g., orbital cellulitis or dysthyroid eye disease).

Haematoma. Blunt or penetrating injury to the orbit may result in haemorrhage in the orbit. The resulting haematoma can compress the optic nerve.

Air in the orbit. An orbital fracture can result in optic nerve compression. If a patient with an orbital fracture blows her or his nose, air may be forced from the paranasal sinus through the fracture and into the orbit, causing pressure on the optic nerve.

Management

Optic nerve compression due to soft tissue swelling or a haematoma

If you suspect optic nerve compression due to soft tissue swelling or a Haematoma, perform a lateral canthotomy to decompress the orbit (see panel).

Optic nerve compression due to soft tissue swelling may also be treated using systemic steroids. Ideally, this would be with 1 g intravenous methyl prednisolone daily for 3 days. However, if this drug is unavailable, oral prednisolone 1 mg/kg for 5 days would be a reasonable substitute. These are high doses of steroids, so it is important to watch for possible side-effects.

In acute cases, you may need to aspirate blood from a haematoma. Use a 5 ml syringe and the same needle placement that is used when administering a peribulbar local anaesthetic.

Optic nerve compression due to air in the orbit

Patients with an orbital fracture should be instructed not to blow their nose for at least six weeks to allow the fracture to heal and to prevent optic nerve compression.

If a patient does blow their nose after an orbital fracture, and they experience a sudden loss of vision in the eye, with proptosis and an afferent pupil defect, they should immediately have the orbit decompressed. Release the air in the orbit using a 5 ml syringe and the same technique that is used to aspirate blood from a haematoma. This should result in an immediate improvement in optic nerve function and vision.

Emergency kit

The contents of an emergency kit to deal with optic nerve compression should include:

- Local anaesthetic for a lateral canthotomy
- Straight scissors for a lateral canthotomy
- 5 ml syringe and 21-gauge needle to aspirate blood or air from the orbit.

Performing a lateral canthotomy

- If you think it needs to be done, do it as soon as possible
- Infiltrate the lateral canthus with local anaesthetic
- Use sharp, straight scissors. Make a good, clean cut about 1 cm in length (see Figure 1) from the lateral canthal fold to the lateral orbital rim (zygoma)
- Leave the wound open. Repair once the intraocular pressure has decreased.

References

1 Risheim H, Sneve M. Bleeding behind the eye. Tidsskr Nor Legeforen 2014;134: 1854 doi: 10.4045/tidsskr.13.071.

2 Broadway D. How to test for a relative afferent pupillary defect (RAPD). Comm Eye Health 2012;25(79 & 80): 58–59.

Emergency management: retinal detachment

David Yorston
Consultant Ophthalmologist: Tennent Institute of Ophthalmology, Gartnavel Hospital, Glasgow, Scotland, UK.

As life expectancy, cataract surgery and myopia increase, retinal detachment will become more common. Early recognition and referral is essential.

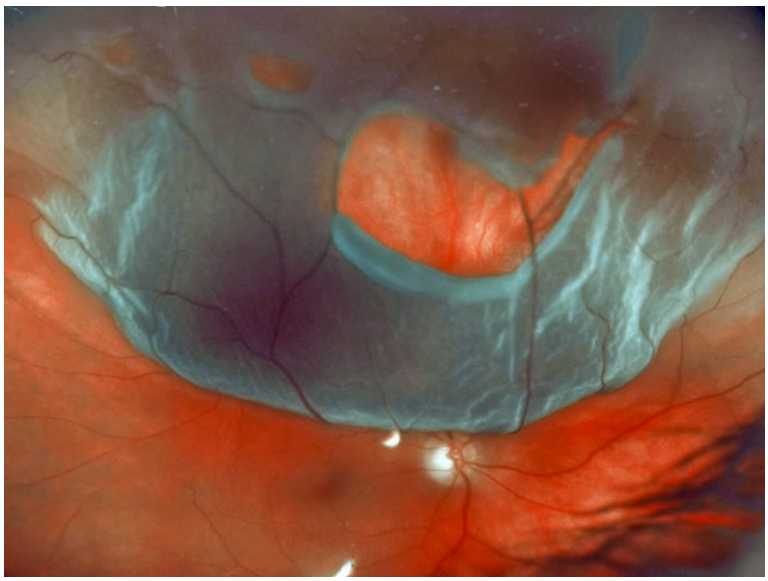

GARTNAVEL HOSPITAL

Figure 1 A detached retina, visible as a grey, mobile membrane in the eye

The retina is the light-sensitive part of the eye. The outer layer of the retina is composed of photoreceptor cells, which generate a nerve signal in response to light. Normally, this photoreceptor layer is in close contact with the choroid and retinal pigment epithelium. The photoreceptor cells depend on this contact for their metabolism. If they are separated from the choroid by a retinal detachment, they may be irreversibly damaged. This is why retinal detachment is an ophthalmic emergency.

As the eye ages, the vitreous becomes liquid, and eventually collapses. When this happens, it may pull on the retina, causing a retinal tear. Fluid then passes through the retinal tear and into the potential space between the retina and choroid. This causes a retinal detachment, which may progress rapidly.

The risk factors for retinal detachment are:

- Age (most common in patients aged 50–70)
- Gender (more common in men)
- Cataract surgery, particularly if it was complicated by vitreous loss
- Myopia (more common in longer-sighted eyes).

> **"If you recognise it early, and refer immediately, you will save the patient's sight."**

Symptoms

The initial symptoms of retinal detachment include a sudden increase in floaters, sometimes with flashes of light in the peripheral vision. As the detachment progresses, there may be a corresponding visual field defect. When the macula detaches, there will be a sudden and severe loss of vision, usually to less than 6/60.

Clinical signs

- The detachment is visible as a grey, mobile membrane inside the eye (Figure 1)
- Intraocular pressure may be reduced
- The red reflex is usually pale, or grey, rather than the normal orange
- When examining the eye using a slit lamp, you may see pigment cells in the vitreous.

To recognise a retinal detachment, you need to examine the retina. Ensure that you have enough training and practice to develop this skill. Check that the ophthalmoscope works, and that spare bulbs and batteries are available.

Treatment

Retinal detachment is treated using surgery. The aim of surgery is to close the retinal break. This stops fluid from leaking under the retina and allows it to re-attach. This can be done either by removing the vitreous (using vitrectomy) and filling the eye with a bubble of gas that holds the retina in place, or by stitching a piece of plastic to the sclera (a scleral buckle). This pushes the outer layers of the eye against the break and plugs it. Approximately 85% of retinal detachments can be cured with a single operation. However, the eye will only regain good vision if the operation is carried out soon after the retina detaches.

Referral

Not all clinics provide retinal surgery, so find out where your nearest retinal detachment surgeon is based. You should be able to explain to the patient how much the treatment will cost, and how to get to the clinic. You should know the contact details of the surgeons so that you can phone to tell them the patient is coming.

If you recognise retinal detachment early, and refer immediately, you will save the patient's sight.

Be prepared

- Familiarise yourself with the symptoms and signs of retinal detachment
- Ensure you have an ophthalmoscope that works and that spare batteries and bulbs are available
- Find out where your nearest retinal detachment surgeon is based and keep their contact details that everyone in the clinic can access easily
- Practise examining the retina.

Emergency management: angle-closure glaucoma

Desirée Murray
Lecturer in Ophthalmology: Department of Clinical Surgical Sciences, The University of the West Indies, Mount Hope, Trinidad and Tobago, West Indies.

Acute angle-closure glaucoma is an ophthalmic emergency as it can lead to irreversible blindness if not identified and treated immediately.

Presentation

The patient may complain of a painful red eye, headache, blurred vision, haloes, nausea, vomiting and abdominal pain (sometimes misdiagnosed as gastroenteritis). Precipitating factors include dim light and certain drugs (e.g., bronchodilators, cough mixtures, cold and flu medication, antidepressants, antihistamines and anticonvulsants).

Examination

Examination findings include conjunctival injection around the cornea (red eye), mid-dilated nonreactive pupil, corneal haze, diminished red reflex and a hard globe, with intraocular pressure (IOP) of between 50 and 80 mmHg. Central retinal artery and central retinal vein occlusion may also occur.

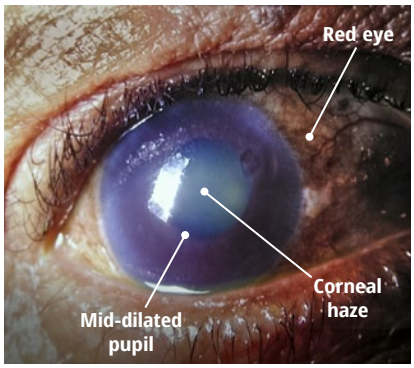

N DU TOIT AND L VAN ZYL, 2013

Figure 1 Clinical findings in acute angle-closure glaucoma.

Protocol

Treatment goal: immediate lowering of IOP and alleviation of inflammation, pain, nausea.

1. Relieve pupil block. Ask the patient to lie down on her or his back. This improves the lens position (it will be more posterior) and thereby relieves pupil block.

2. Lower IOP. Give acetazolamide 500 mg, preferably intravenously or orally, if intravenous is not available or if the patient is not nauseated. Instil topical glaucoma medications (beta blockers, alpha agonists and prostaglandin analogues).

3. Reduce pain by giving analgesics and **reduce inflammation** by instilling topical steroids.

4. Reduce nausea and vomiting. Give anti-emetics.

After approximately 1 hour, the decrease in IOP should improve blood supply to the iris and make it more responsive to pilocarpine.

Instil pilocarpine (2% or 4% eye drops) in two doses, spaced 15 minutes apart. If IOP remains dangerously elevated after the second dose of pilocarpine, consider giving hyperosmotic agents such as glycerol, isosorbide or mannitol. **Extreme caution is advised in patients with cardiovascular conditions and renal impairment, as the side effects can be life-threatening. Glycerol is contraindicated in patients with diabetes.**

Referral and treatment

Once the patient is stabilised, refer her or him to an ophthalmologist immediately.

Because the lens plays a major role in the mechanism of acute angle-closure glaucoma, cataract extraction can be considered as a definitive treatment for patients with co-existing cataract and presenting IOP >55 mmHg.[1] After the acute attack is successfully treated with medication, the cataract is replaced by a thinner artificial lens implant, thereby relieving the pupil block.

DESIRÉE MURRAY

Figure 2 Peripheral iridotomy

In other patients, the basis of treatment is an iridotomy: the creation of a hole in the peripheral iris (Figure 2), either surgically or using a laser. This bypasses the pupil block and reestablishes flow from the posterior to the anterior chamber. If the other eye is at risk, iridotomy is performed in both eyes.

How to prepare for this emergency

Put together an acute angle-closure glaucoma emergency kit containing all the medication (see panel),[2] needles and syringes that may be needed. Include a copy of the treatment protocol and the contact details of the nearest ophthalmologist. This will ensure that you and your team are prepared. Check expiry dates regularly as this sight-threatening emergency is uncommon. The storage container should be clearly labelled and kept in the emergency room for easy access. Every team member must know where the kit is stored and be familiar with its contents.

Emergency kit: medication

- Intravenous acetazolamide 500 mg, provided as a sterile powder requiring reconstitution (or oral acetazolamide if intravenous is unavailable)
- Hyperosmotic agents
  - Oral glycerol 1.0–1.5 g/kg (*contraindicated in patients with diabetes*)
  - Oral isosorbide 1.5–2.0 g/kg (*as an alternative in patients with diabetes*)
  - Intravenous mannitol 1–2 g/kg (500 ml of 20%)
- Topical steroids (prednisolone)
- Topical glaucoma drugs
  - Beta blocker (timolol)
  - Alpha 2 agonist (brimonidine, apraclonidine)
  - Prostaglandin analogue (latanoprost, travoprost, bimatoprost)
- Topical pilocarpine 2% or 4%
- Non-oral analgesics (or oral if other routes are not available)
- Non-oral anti-emetics (or oral if other routes are not available)
- Contact details of the nearest ophthalmologist (on-site or off-site) for emergency referral.

References

1 Lam DSC, Leung DYL, Tham CCY, Li FCH, Kwong YYY, Chiu TYH, Fan DSP. Randomized trial of early phacoemulsification versus peripheral iridotomy to prevent intraocular pressure rise after acute primary angle closure. Ophthalmology 2008;115(7):1134-1140.

2 IAPB Essential List for Glaucoma. Available at **https://iapb.standardlist.org/wp-content/uploads/2017/04/IAPB_EL_for_Glaucoma_2017.pdf** (accessed 10 June, 2018).

Emergency management: vitreous loss

William Dean
Clinical Research fellow: London School of Hygiene and Tropical Medicine, London, UK.

The most common mistake when managing vitreous loss is to leave some of it behind in the anterior chamber or up to the wound. Knowing when to stop using the vitrector, and how to tell whether there is any vitreous remaining, is crucial.

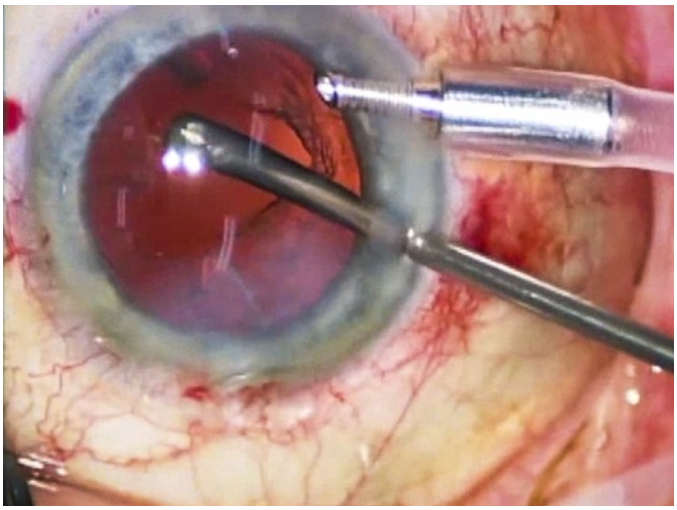

WILLIAM DEAN

Vitrectomy after a posterior capsular tear with vitreous loss.

A posterior capsular tear (PCT) with vitreous loss is an emergency that can occur at different stages of a cataract operation.

Signs include sudden deepening of the anterior chamber, momentary dilation of the pupil, visible vitreous, a visible PCT, a peripheral clear red reflex, and/or excess movement of the nucleus.

All cataract surgeons need to know how to manage vitreous loss safely. It is never acceptable to leave vitreous in the anterior chamber, especially if it extends to the main wound or paracentesis.

Differential diagnoses may include a simple fold in the posterior capsule, which may appear like the edge of a PCT. Soft lens matter may mimic the peripheral clear red reflex of a PCT.

Remedies and immediate management
Once vitreous loss has been diagnosed, it must be effectively managed. Do not panic. Stop any aspiration, calmly assess the situation, then gently remove the instruments from the eye. If possible, inject dispersive viscoelastic into the anterior chamber before removing the instruments.

Step 1: Release the pressure on the eye

- Make a superior rectus suture
- Consider 'lifting' the speculum forwards
- Reduce the pressure of irrigation and aspiration (Simcoe or automated) when re-inserted into eye
- Reduce the height of the irrigation fluid bag
- Do not exert pressure on the globe with scleral fixation or other forceps.

Step 2: Remove the vitreous
When using an automated vitrector, keep the **aspiration (vacuum) rate low** and the **cut rate high**. Keep the **irrigation (infusion) rate low**. Vitreous is cut and removed at the site of the PCT, around the pupil margin, and in the anterior chamber. Perform a limited anterior vitrectomy through the PCT. Stop using the vitrector when you are confident there is no further vitreous in the anterior chamber.

A manual sponge vitrectomy is performed using a cellulose non-fragmenting spear (Figure 1). Depress this on the posterior wound to express vitreous, and then cut the vitreous using sharp intraocular scissors such as De Wecker's or curved Westcott's. Repeat until there are no more strands of vitreous coming to the wound and the sponge.

Triamcinolone 40 mg/ml stains the vitreous strands white when injected into the anterior chamber, which makes it much easier to do a complete vitrectomy. A simple technique is to use a viscoelastic cannula to sweep just above the iris, underneath the wounds. If there are strands of vitreous, the cannula will catch them and the pupil will peak. These strands need to be cut.

Remove all vitreous from the anterior chamber, especially from wounds: don't leave an oval pupil. Preserve as much of the lens capsule as possible. After vitrectomy, only insert a posterior chamber IOL if you are sure there is sufficient capsule to hold it in place.

Step 3: Check that all the vitreous has been removed
Make final checks to identify any vitreous remaining in the anterior chamber and any strands of vitreous extending to wounds. Acetylcholine 20 mg/ml solution or preservative-free pilocarpine (2% or 4% drop diluted in 1 ml normal saline) may be injected into the anterior chamber after posterior chamber IOL insertion. This causes pupil constriction, so if there are any strands of vitreous remaining these will cause a 'peaked' pupil.

Step 4: Referral
If a posterior-capsule tear occurs and any part of the cataract nucleus drops into the vitreous, then urgent referral to a vitreo-retinal specialist is needed. Never try to retrieve nucleus fragments from the vitreous, as this will damage the lens capsule, iris, and cornea, and make surgery much more difficult in future.

How to prepare for this emergency
With the theatre team, practise setting up the vitrector, if one is available. Do this until everyone feels competent.

If you have access to a wet lab or surgical skills centre, practise using animal eyes or by injecting egg white into the posterior chamber of an artificial eye and causing a PCT with a needle. Effective management of vitreous loss should be practised away from the patient and the stress of a live complication.

Figure 1 Instruments used to manage vitreous loss

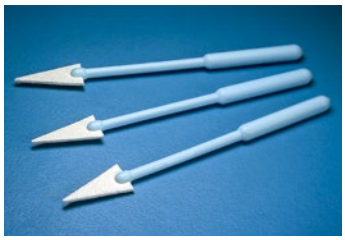

Cellulose non-fragmenting spear

Automated vitrector

De Wecker's scissors

Emergency management: microbial keratitis

Simon Arunga
Clinical Lecturer and Ophthalmologist: Mbarara University and Regional Referral Hospital Eye Centre, Mbarara, Uganda.

Matthew Burton
Professor of International Eye Health: International Centre for Eye Health, London School of Hygiene & Tropical Medicine, London, UK.

Microbial keratitis requires prompt diagnosis and immediate treatment to prevent severe loss of vision.

Microbial keratitis is an infection of the cornea that can be caused by bacteria, fungi or protozoa such as *Acanthamoeba spp*. In low- and middle-income countries, management is often more challenging because of late presentation, the use of traditional eye medicines, insufficient diagnostic support, a lack of effective drugs and insufficient keratoplasty services.

Our experience in East Africa is that most patients will visit a primary health centre within a day or two of onset of symptoms, but may take another two weeks to reach the eye unit; by which time it can be too late to save the eye. All health care workers, including front-line primary health workers, must therefore know how to identify microbial keratitis early, provide immediate treatment, refer patients for specialist treatment and make sure they are able to take up the referral.

Detecting microbial keratitis

The clinical presentation of microbial keratitis has been covered in detail in previous editions of this journal.[1,2]

Patients usually present with reduced vision, pain, discharge, and red eyes. They may have a history of trauma and traditional eye medicine use.

Measure visual acuity first and record it, then examine the eye to look for signs of microbial keratitis.

Equipment

- A torch with a bright light, a direct ophthalmoscope, or the Arclight
- Fluorescein strips
- A blue light source. You can use a simple blue-coloured filter (a thin plastic sheet) on your light source
- Magnifying loupes or a simple pair of reading glasses can be helpful for seeing finer details, such as a corneal foreign body.

Signs

Look for signs of:

- Ciliary injection: a red eye that involves the branches of the anterior ciliary arteries
- Corneal infiltrate: creamy white material in the cornea
- A hypopyon: creamy white material that has collected at the bottom of the iris (Figure 1)
- A corneal epithelial defect which shows up as green with fluorescein staining (Figure 2).

Write down and draw all your observations, including the size, shape and location of any lesions.The patient in Figures 1 and 2 has advanced microbial keratitis.

Initial management

A **corneal abrasion** (Figure 3) may develop into microbial keratitis. At primary level, give chloramphenicol eye ointment 3 times a day for 3 days. Look for a corneal foreign body and refer if present. Treat as microbial keratitis if it has not resolved after 3 days.

Refer patients urgently if you suspect **microbial keratitis**. Prescribe broad-spectrum antibiotic eye drops with instructions to instil them hourly, day and night (as long as the patient is awake), until they are seen at the referral centre. Microbial keratitis should be managed in a setting where full microbiology investigation and clinical assessment can be performed. Management of microbial keratitis, including the preparation of fortified antibiotics, has been described in this journal previously.[1,3]

SIMON ARUNGA

Figure 1 Microbial keratitis with ciliary injection, corneal infiltrate and a hypopyon. This patient also has satellite lesions superiorly

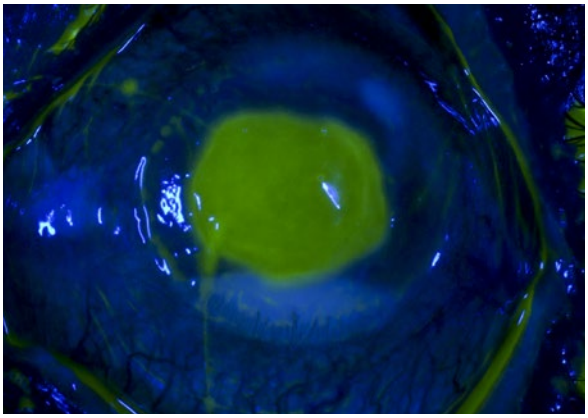

SIMON ARUNGA

Figure 2 Microbial keratitis. The corneal epithelial defect shows up green with fluorescein staining

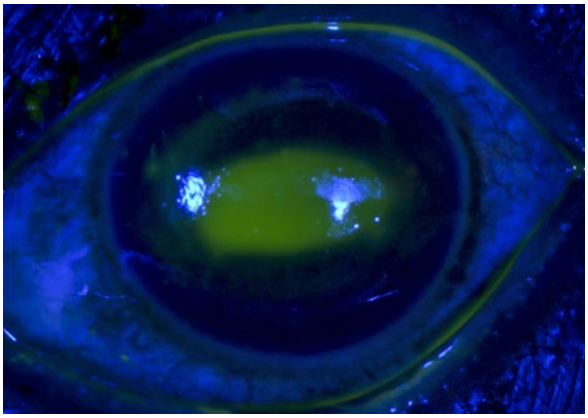

SIMON ARUNGA

Figure 3 Fluorescein staining confirms the presence of a corneal abrasion

The referral process

Referral is not simple for the patient. Many live in rural areas and referral means travelling long distances to a large urban eye unit that they have never been to before, incurring considerable expenses. These are barriers to the referral process and need to be considered.

In your referral letter, document your findings, including baseline measurements, initial treatment and reason for referral, and then contact the referral centre about the patient. Prior notice also helps the referral centre to prepare the necessary items such as agar plates.

Patients must feel supported and need to know that someone will be expecting them. This might mean giving them a phone number to call when they arrive.

Explain the purpose and urgency of the referral in order to ensure that the patient attends. Microbial keratitis, especially fungal infections, tend to resolve slowly, and counselling helps to manage patients' expectations and keep them hopeful.

How you can be prepared

- Equip your health facility with a torch, fluorescein strips and broad-spectrum antibiotics
- Ensure that the details of the nearest referral centre are clearly written down, where everyone can see it
- Ensure that everyone in the team knows how to prepare broad-spectrum antibiotics and has access to printed instructions for doing so
- Print out a decision-making guide and referral checklist and display these in your clinic.

Referral checklist

- Baseline examination, including visual acuity, done and recorded
- Initial treatment started and documented in detail
- Reason for referral documented clearly and communicated to the patient
- Patient understands the expected healing prognosis and timeframe
- Referral centre contacted
- Patient knows when the referral centre is open and is given clear directions
- Patient is given the phone number of the coordinator at the referral centre to call once they arrive so that they are seen urgently.

References

1 Upadhyay MP, Srinivasan M, Whitcher JP. Diagnosing and managing microbial keratitis. Community eye health. 2015;28(89):3.

2 Leck A, Burton M. Distinguishing fungal and bacterial keratitis on clinical signs. Community eye health/International Centre for Eye Health. 2015;28(89):6-7.

3 Upadhyay MP, Srinivasan M, Whitcher JP. Managing corneal disease: focus on suppurative keratitis. Community eye health. 2009;22(71):39

How to make fluorescein strips

Gilbert Arinda
Ophthalmic Nurse, Mbarara University and Regional Referral Hospital Eye Centre, Mbarara, Uganda

Simon Arunga
Clinical Lecturer and Ophthalmologist: Mbarara University and Regional Referral Hospital Eye Centre, Mbarara, Uganda.

Fluorescein strips are an essential diagnostic tool in eye care. They are useful for performing a number of procedures, such as measuring intraocular pressure, assessing dry eye and detecting corneal abrasions. Unfortunately, this basic item is not commonly available in many resource-limited settings. Here we describe how we make fluorescein strips at Mbarara University and Regional Referral Hospital Eye Centre.

What you will need

- Sterile filter paper (e.g., Whatman no. 1)
- A sterile bowl, such as a kidney dish
- Fluorescein sodium powder (20g)
- Distilled sterile water (100ml)
- A pair of scissors
- Empty injectable vials or any other small, sealed containers
- A sterile surface
- Sterile gloves, mask and apron.

Procedure

- Assemble all the materials on a clean tray
- Put on sterile gloves, mask and apron
- Prepare a 20% fluorescein solution by dissolving 20g of fluorescein sodium powder in 100ml distilled, sterile water
- Cut the filter paper into rectangles of approximately 5cm wide and 8–10cm long
- Pour a small amount of fluorescein solution into the bowl. Be careful not to spill, as fluorescein leaves stains
- Dip the long edge of the filter paper in the fluorescein solution and immediately remove it, as the solution spreads very quickly through the paper (Figure 1)
- Place the dipped filter papers onto a sterile surface to dry
- Once they are dry, use a pair of scissors to cut the paper into strips, with the dipped edge at one end (Figure 2)
- Store the strips in a sterile, sealed container (Figure 3).

Figure 1 Dip the long edge of the filter paper rectangle in the fluorescein solution



GILBERT ARINDA

Figure 2 Cut the paper into strips with the dipped edge at one end

GILBERT ARINDA

Figure 3 Store the strips in a sterile, sealed container

GILBERT ARINDA

Emergency management: acute endophthalmitis

Nuwan Niyadurupola
Consultant Ophthalmic Surgeon & Honorary Senior Lecturer: Ophthalmology Department, The Norfolk and Norwich University Hospital NHS Trust, Norwich, UK.

Endophthalmitis can have devastating consequences for a patient's eye and vision. Prompt recognition and urgent treatment are vital.

DAVID YORSTON

Endophthalmitis. The eyelids are swollen, the eye is red and a hypopyon is clearly visible.

How to recognise endophthalmitis

1. Suspect endophthalmitis if **any** of the following symptoms or clinical signs are present, particularly if there is a previous history of surgery, intravitreal injection or penetrating trauma:

- Blurred vision
- Pain
- Red eye
- Hypopyon
- Vitreous opacities
- Swollen eyelids
- Poor red reflex

2. Perform B-scan ultrasonography (if available) to check for vitritis or retinal detachment.

3. Do not try to treat with a course of corticosteroids first – this will delay treatment and may result in losing the eye.

Protocol: How to respond to the condition

Do not delay! Treat as a medical emergency

Within 1 hour

- Perform an intravitreal tap or vitrectomy through the pars plana (see panel). Collect samples of vitreous for Gram stain and culture. A vitrectomy may be indicated if the patient has perception of light only. *However, if a delay is likely before a vitrectomy can be performed, it is advisable to perform a vitreous tap and inject intravitreal antibiotics for more rapid treatment*
- Immediately following the intravitreal tap, inject antibiotics into the vitreous (see panel)
- After injecting intravitreal antibiotics, use a different syringe and a 30-gauge needle to inject preservative-free dexamethasone (400 µg in 0.1 ml) into the vitreous.

Then

- Consider adjunctive systemic therapy, with the same antibiotics as those used intravitreally, for 48 hours. This will maintain higher levels within the posterior segment of the eye. If systemic antibiotics are not available, topical antibiotics are better than nothing
- Monitor the patient carefully
- Use the response to treatment and the results of Gram stain and culture to determine whether further intravitreal antibiotic therapy is required.

Technique: How to do an intravitreal tap

- Use aseptic technique with drape
- Instil topical antibiotics and povidone iodine 5%
- Administer subconjunctival or sub-Tenon's anaesthetic
- Insert a 23-gauge or 25-gauge needle 4 mm (phakic eyes) or 3.5 mm (pseudoaphakic/aphakic eyes) behind the limbus into the middle of the vitreous cavity, pointing at the optic disc (approx 7–8 mm deep) and aim to aspirate 0.3–0.5 ml of vitreous fluid.

Antibiotics

1st choice:
- Vancomycin 1 mg in 0.1 ml and
- Ceftazidime 2 mg in 0.1 ml

OR

2nd choice:
- Amikacin 400 µg in 0.1 ml and
- Ceftazidime 2 mg in 0.1 ml

Note: Use a new syringe and a new 30-gauge needle for each drug. Do not mix drugs together in the same syringe.

Preparing for the emergency

An endophthalmitis kit should be accessible in every practice where postoperative patients are seen. This is essential for the prompt diagnosis and treatment of endophthalmitis. Include instructions for preparing the antibiotics (see p. 69).

Equipment for preparation of patient

- Tetracaine (anaesthetic) drops
- Povidone iodine
- Drape
- Speculum

Equipment for sub-Tenon's anaesthetic injection

- 10 ml 2% lidocaine
- 10 ml syringe
- Sub-Tenon's cannula
- Westcott scissors

Equipment for vitreous biopsy/tap

- 23-gauge or 25-gauge needle
- 5 ml syringe
- Calipers

Equipment for preparation of antibiotic injections

- 1 vial of 500 mg vancomycin or 1 vial of 500 mg (250 mg/ml) amikacin
- 1 vial of 500 mg ceftazidime
- 3 x 10 ml sodium chloride 0.9% injection (saline)
- 4 x 10 ml syringe
- 2 x 5 ml syringe
- 2 x 1 ml syringe
- 1 x sterile galley pot (for amikacin)
- 6 x 21-gauge needles for preparation of antibiotics
- 2 x 30-gauge needles for intravitreal injection

Instructions for preparation of antibiotic injections

Vancomycin 1 mg/0.1 ml

- Reconstitute 500 mg vial with 10 ml saline
- Withdraw all 10 ml into 10 ml syringe
- Inject 2 ml of this solution back into vial
- Add 8 ml saline into vial to make up to 10 ml (10 mg/ml)
- Use 1 ml syringe to draw 0.1 ml of this solution (1 mg/0.1 ml)

Amikacin 400 µg/0.1 ml

- Use 10 ml syringe to withdraw 1.6 ml of amikacin (250 mg/ml)
- Make up to 10 ml in the syringe with saline
- Discard 9 ml from syringe and make the remaining 1 ml up to 10 ml (in the syringe) by adding saline
- Transfer the solution into a sterile galley pot and use 1 ml syringe to draw 0.1 ml of this solution (400 µg/0.1 ml)

Ceftazidime 2 mg/0.1 ml

- Reconstitute 500 mg vial with 10 ml saline
- Withdraw all 10 ml into a 10 ml syringe

Futher reading

ESCRS Endophthalmitis Study Group. Prophylaxis of postoperative endophthalmitis following cataract surgery: results of the ESCRS muticenter study and identification of risk factors. J Cataract Refract Surg 2007;33:978–988.

Endophthalmitis Vitrectomy Study Group. Results of the Endophthalmitis Vitrectomy Study. A randomized trial of immediate vitrectomy and of intravenous antibiotics for the treatment of postoperative bacterial endophthalmitis. Arch Ophthalmol 1995;113:1479– 1496.

Emergency management: exposure keratopathy

Wanjiku Mathenge
Consultant Ophthalmologist and Director of Training and Research: Rwanda National Institute of Ophthalmology and Dr Agarwal's Eye Hospital, Kigali, Rwanda.

Exposure keratopathy can result in destruction of the cornea and blindness if not treated urgently.

Exposure keratopathy (also known as exposure keratitis) is damage to the cornea due to dryness caused by incomplete or inadequate eyelid closure, resulting in loss or insufficiency of the tear film. It is usually a mild condition that is simple to treat. However, it can become an eye emergency in the following situations:

- In unconscious patients in intensive care units, when there is inadequate lid closure
- In patients with a facial nerve palsy, which causes paralysis of the eyelids
- In patients who experience a sudden bleed behind the eye (e.g., after a peribulbar or retrobulbar block)
- In patients who have a condition, such as a tumour, that pushes the eye forward and makes it impossible for the eyelids to close (lagophthalmos)
- Following severe damage to the eyelids (particularly the upper lid), such as trauma, burns or scarring from *Herpes zoster* infection
- If corneal sensation is reduced (e.g., following *Herpes zoster* infection). This makes the eye particularly vulnerable to exposure.

If the keratopathy becomes severe, there is a very high risk of irreversible blindness within a matter of hours or days, so treatment must begin immediately.

Signs and symptoms

In severe cases, the cornea will look dry and may ulcerate, leading to perforation. Patients will experience pain or irritation, foreign body sensation, burning, blurring of vision, watering, redness and sensitivity to light.

Examination

Assess lid closure and corneal sensitivity. Perform fluorescein staining of the cornea to assess for infection, thinning, scarring or perforation of the cornea.

Management

Aim to cover, protect and lubricate the cornea.

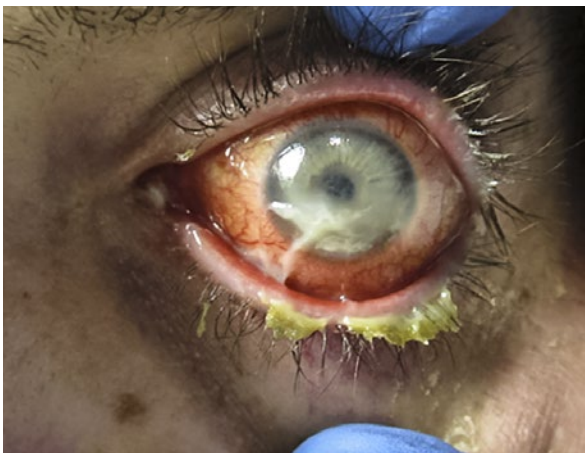

RISMA JM, SYED NA (2014)

Severe keratopathy with ulceration and keratinisation of the cornea.

In the case of a sudden bleed, perform a canthotomy (p. 62) to relieve pressure and allow the eyelids to close.

In case of proptosis from other causes, take care to protect the cornea from exposure where lid closure is compromised. Prescribe frequent lubricating drops (preservative free if possible to avoid toxicity) during the day and lubricating ointment at night.

In patients who cannot close their eyes, either because they are unconscious, or because of a facial nerve palsy, apply lubricating gel and close the eyelid. This can be as simple as a patch, or lid closure using tape. The lids can also be closed using temporary sutures such as a Frost suture, or partially closed by creating a temporary or permanent tarsorrhaphy.[1]

If the eyelids cannot be closed due to loss of the eyelid or severe proptosis, the cornea can be protected using a moisture chamber. A low-cost moisture chamber can be made using plastic wrap.

When to refer

Patients with sight-threatening complications such as persistent corneal ulceration, microbial keratitis, perforation and corneal scar should be seen by a specialist. Patients with exposure and reduced corneal sensation should also be referred.

Protecting unconscious patients

Reach out to intensive care unit personnel to explain the dangers of exposure and encourage early detection and referral. Prescribe lubricating drops or ointments to all at risk.

Further reading

Rajak S, Rajak J, Selva D. Performing a tarsorraphy. Comm Eye Health 2015;28(89): 10-11.

Emergency management: penetrating eye injuries and intraocular foreign bodies

Nyawira Mwangi
Research Fellow: London School of Hygiene and Tropical Medicine, London, UK.

Dorothy M Mutie
Ophthalmologist/ Lecturer: Kenya Medical Training College, Nairobi, Kenya.

Penetrating injuries require immediate first aid and urgent referral to a specialist, particularly if there is a foreign body in the eye.

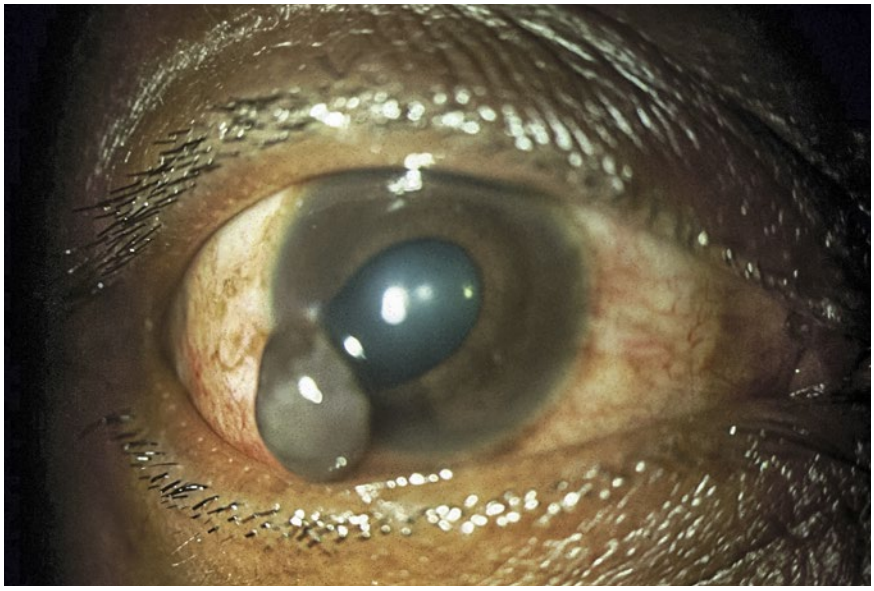

HELEN KELLER INTERNATIONAL

A penetrating eye injury with iris prolapse.

Up to 40% of penetrating eye injuries are complicated by the presence of an intraocular foreign body (IOFB).[1,2] It may be toxic (iron, copper, vegetable matter) or inert (glass or plastic). Vision loss may result from the mechanical injury or from post-traumatic complications such as endophthalmitis, retinal detachment, metal toxicity and sympathetic ophthalmia.[2] Prompt diagnosis, referral, removal of the IOFB and surgical repair will help to preserve the visual acuity and the globe anatomy.

Recognition and diagnosis

When the patient presents, conduct an initial trauma assessment and resuscitation (if necessary) using the airway-breathing-circulation-disability-exposure (ABCDE) systematic approach.[3] Ask about systemic comorbidities, allergies to medication and time of last meal. Non-ocular injuries, such as head injuries, should be managed with the help of other specialists.

What to ask when taking a history (ATMIST-V):

A	**A**ge of patient
T	**T**ime and date of injury
M	**M**echanism (sharp object, hammer and chisel, sawing, grinding, explosives, broken windscreen, etc) and setting (work, home, gardening, assault, motor accident etc)
I	**I**njuries sustained
S	**S**ymptoms and signs (pain, redness, decreased vision)
T	**T**reatment or intervention already given
-	
V	**V**isual status before injury (previous history and surgery) and whether any protective eye wear was worn

A retained IOFB in the posterior segment is usually hidden from view (occult). Assume that the patient has a retained IOFB until proven otherwise, even after a long period of time.[1,2]

Record the baseline best-corrected visual acuity in each eye and conduct a complete examination of both eyes and adnexae. Use Desmarre's retractor to avoid undue pressure on the globe during examination.

History and clinical findings that should raise the suspicion of an IOFB include: a history of hammering a metal object, a scleral wound with uveal prolapse, a corneal entry point with oedema, a shallow anterior chamber, an iris hole, an irregular pupil, a lens defect and vitreous haemorrhage.

Remedies and immediate management

After examination, you should:

1. Protect the eye from further damage by using an eye shield.
2. Administer systemic analgesics.
3. Administer prophylactic broad-spectrum systemic antibiotics.
4. Administer anti-emetics if the patient has nausea or vomiting.
5. Update tetanus prophylaxis.
6. Recommend 'nil by mouth' status in preparation for surgery.
7. Carefully document all findings and actions taken.

Take note:

- Defer IOP measurements in patients with lacerations
- Avoid any pressure on the globe; for example, do not press on the sclera
- **Do not** attempt to pull out any foreign material that may be sticking out of the eye.

Referral

Refer the patient **urgently** to a facility that has the following:

- An ophthalmic surgeon who is equipped for pars plana vitrectomy (required for posterior IOFB)
- Imaging facilities: orbital X-ray and ultrasound, and CT scan. MRI is contraindicated until you have excluded the possibility of a metallic IOFB
- An operating theatre where urgent removal of IOFB, intravitreal antibiotic injection and surgical repair can be done.

Gently explain to the patient that multiple operations may be required and that visual prognosis is uncertain, but taking up the referral as quickly as possible will give them the best chance. Send the patient with a comprehensive referral note and alert the surgeon.

Rehearsal

In preparation for handling such a patient, you need to ensure that your clinic has the following items:

- **Equipment.** Desmarre's eye retractor, rigid eye shield, tape, standard examination equipment
- **Drugs.** Analgesics, antibiotics, anti-emetics, tetanus vaccine
- **Information.** Contact details of the nearest referral centre that can provide vitrectomy surgery.

Practise the following:

- Taking consent (and assent from children)
- Speaking with the patient about the visual prognosis
- Writing a referral note.

References

1 Parke DW, Flynn HW, Fisher YL. Management of intraocular foreign bodies: a clinical flight plan. Can J Ophthalmol 2013;48:8-12.

2 Loporchio D, Mukkamala L, Gorukanti K, Zarbin M, Langer P, Bhagat N. Intraocular foreign bodies: A review. Surv Ophthalmol 2016;61:582-596.

3 Mutie D Mwangi N. Assessing an eye injury patient. Comm Eye Health J 2015;28(91):46-48.

How to apply an eye shield

Nyawira Mwangi and **Dorothy M Mutie**

Rationale

Applying an eye shield protects an injured eye from further damage.

What you need

- Tape
- A rigid eye shield

If you do not have an eye shield, make one by cutting out a round piece of card approximately 8 cm in diameter. Make a single cut from the edge to the centre. Overlap the two edges and secure in place with tape to form a shallow cone (Figure 2).

Instructions

1 Explain to the patient that the eye needs to be protected.
2 Ensure that there is good lighting.
3 Wash your hands.
4 Prepare the eye shield.
5 Ask the patient to close the affected eye.
6 Clean and dry the skin around the eye, as well as the forehead and cheek. This will allow the tape to hold fast.
7 Place the shield carefully over the eye. Ensure that the edges rest comfortably on the bones around the eye and not on the eye itself, or on the soft tissues surrounding it, as this can cause further damage.
8 Cut an appropriate length of tape (Figure 3).
9 Use the tape to hold the shield in place (Figure 4).

DOROTHY MUTIE

Figure 1 Rigid eye shield and tape

PAK SANG LEE

Figure 2 You can make your own eye shield using an oval piece of card

DOROTHY MUTIE

Figure 3 Cut an appropriate length of tape

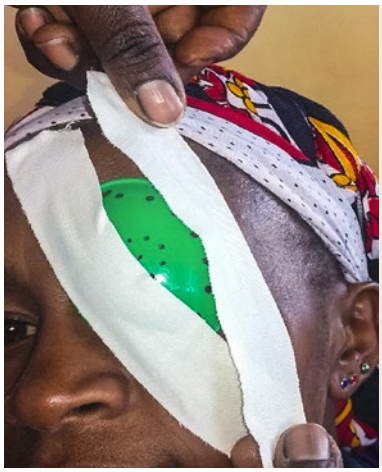

DOROTHY MUTIE

Figure 4 Apply tape to hold the shield in place

Emergency management: chemical burns

Millicent Bore
Cornea and Anterior Segment Specialist: Lecturer University of Nairobi, Kenyatta National Hospital, Nairobi, Kenya.

Chemical injury causes severe corneal scarring, but this can be prevented by immediate irrigation of the eye.

If a patient has suffered a chemical burn in the eye, immediate, high-volume irrigation is essential in order to wash out the chemicals and save her or his vision.[1]

1 Instil anaesthetic eyedrops and follow the protocol in the panel below to irrigate the eye for at least 30 minutes.[2,3]
2 After irrigation, give systemic analgesics and refer the patient to an eye specialist immediately.
3 If you are based in the community, refer patients to the nearest eye centre and tell them they must see an eye specialist very urgently.
4 Take a careful history and send your notes and the referral letter to the ophthalmologist, whether electronically or by hand. Make sure the patient knows where to go, and when. Call the ophthalmologist in advance so they know to expect the patient.

When taking the history, ask:

- When did the injury take place?
- Were the eyes rinsed out afterwards? For how long?
- What type of chemical splashed in the eye? Ask about the packaging
- Was she/he wearing eye protection?
- Accident or assault?

Preparing for this emergency

Emergency management of patients with chemical burns requires preparation. It is important to have eye irrigation kits[2,3] and protocols or standard operating procedures[2,3] available that give clear guidance on what to do if a patient comes to a clinic or hospital with a chemical burn (see panels below). The kits should be easily accessible and everyone in the team must know where they are kept.

PAK SANG LEE

Figure 1 Irrigating the eye using saline solution and a feeding cup (if an IV set is not available). Irrigate for at least 30 minutes and take care not to contaminate the other eye.[2,3]

In a hospital, the personnel in the eye unit should practise and simulate the clinical scenario together with those from the emergency department because they are, in most cases, the patients' first contact when they arrive at the hospital. This preparation will save time, because everyone will know what is needed, where to find it and what role they will play. Time is of the essence, and a prompt response will limit damage to the eyes and save vision. This can only happen if personnel are well prepared.

In conclusion, immediate irrigation influences the final outcome favourably[4] and improves prognosis. It is essential that all eye teams are trained and equipped to irrigate the eye.

Eye irrigation kit

- 2–3 litres of normal saline or Ringer's lactate (if not available, use clean water)
- Intravenous fluid (IV) giving set (or a large syringe or a small receptacle with a pouring spout), such as a feeding cup)
- Towel or gauze swabs
- A bowl or kidney dish
- Drip stand (if available)
- Local anaesthetic drops
- Eye lid speculum
- Retractors, if available
- Clean tissues
- Cycloplegic and antibiotic eyedrops
- An eye pad

Protocol: irrigation following chemical burns

1 Instil topical anaesthetic.
2 Insert lid speculum or use your fingers to gently hold the eyelids open.
3 Irrigate one eye at a time.
4 Tilt the patient's head towards the injured side to help avoid contaminating the other eye. Place a kidney dish ready to receive the fluid and use towels to enhance patient comfort. Ideally, use an IV giving set at full speed. However, in the absence of this, a clean container may be used.
5 Irrigate with normal saline or Ringer's lactate for at least 30 minute. Take care not to contaminate the other eye.
6 Evert the lid. Irrigate the front surface of the eye, including the fornices, slowly and steadily.
7 Ask the patient to move the eye in all directions while the irrigation is maintained.
8 Evert both the eyelids using retractors, then carefully assess for any particulate matter.
9 Remove particles from the ocular surface the corner of a folded tissue.
10 Instil cycloplegic drops (if available) and topical antibiotic eyedrops and pad the eye.
11 Give systemic analgesics.
12 Refer immediately.

References

1 Clare G, Suleman H, Bunce C, Dua H. Amniotic membrane transplantation for acute ocular burns (Protocol). Cochrane Database of Systematic Reviews 2011; Issue 10; Art. No.: CD009379.
2 Stevens S. How to irrigate the eye. Comm Eye Health J 2016;29(95):56.
3 Mutie D, Mwangi N. Managing eye injuries. Comm Eye Health J 2015;28(91):48-49.
4 Mannis J, Holland E. Cornea. Chemical and thermal injuries of the eye. 4th ed. Elsevier, 2017: 1106-1116.

Celebrating 20 years of progress: accelerating towards elimination

Virginia Sarah
Global Partnerships Executive: Fred Hollows Foundation and Immediate Past Chair: International Coalition for Trachoma Control, London, UK.

Aparna Barua Adams
Project Manager: International Coalition for Trachoma Control, London, UK.

Tim Jesudason
Special Projects and Campaigns: International Coalition for Trachoma Control London, UK.

Twenty years after the World Health Assembly adopted a resolution that targeted trachoma for elimination, work is continuing at a rapid pace.

Trachoma is the world's leading infectious cause of blindness and one of twenty neglected tropical diseases (NTDs) that affect over one billion of the world's poorest people. In 1998, the World Health Assembly adopted Resolution 51:11,[1] which targeted trachoma for global elimination. Since then, progress has accelerated.

The number of people at risk of trachoma has more than halved since 2011, thanks to the efforts of stakeholders in the WHO Alliance for the Global Elimination of Trachoma by 2020 (GET2020). Since 2012, eight countries have been validated by WHO as having eliminated trachoma as a public health problem: Oman in 2012, Morocco in 2016, Cambodia, Lao Peoples Democratic Republic and Mexico in 2017, and Ghana, Nepal and the Islamic Republic of Iran in 2018. By the year 2020, it is estimated that at least 70% of endemic districts will have reached the WHO target for elimination as a public health problem: prevalence of trachomatous inflammation-follicular (TF) 1–9 below 5%.

This year's data[2,3] demonstrates the significant global and regional progress made during 2017 and early 2018.

- The number of people at risk of trachoma, because they live in districts where trachoma is endemic, has decreased from 182 million people in 2017 to 157.7 million as of April 2018
- Last year, 231,447 people received surgery for trachomatous trichiasis and 83.5 million were treated with antibiotics
- A total of 140 new districts in endemic countries received antibiotics for the first time in 2017. At the same time, it was reported that 250 districts reached their elimination targets, resulting in 27 million people no longer requiring antibiotic treatment
- For the first time, we are now providing antibiotics to over 50% of the people who need it.

Recently, stakeholders completed the Global Trachoma Mapping Project (2012–2016), which clearly identified the global prevalence of trachoma and helped us to define the actions and resources needed to eliminate trachoma.

The rapid progress shown in the global programme demonstrates that trachoma can be eliminated as a public health problem. However, to achieve global elimination, every endemic community must be reached with treatment interventions. Ethiopia has the greatest need, with 70 million people living in areas where trachoma is endemic (this is 44% of the global population currently at risk of trachoma).

WORLD HEALTH ORGANIZATION

The Islamic Republic of Iran has just become the eighth country to be declared by the World Health Organization as having eliminated trachoma.

To meet our goals, the most marginalised of people – indigenous and nomadic tribes, refugees, internally displaced people, and people living in conflict areas – must be reached. Sustained political will, operational research, new donors and partnerships, as well as financial and human resources will be essential to continue progress towards elimination.

In recent years, progress in the implementation of the WHO-endorsed SAFE strategy (Surgery for trichiasis, Antibiotics, Facial cleanliness and Environmental improvement) has been marked by unprecedented partnerships and coordination among donors, implementing organisations and ministries of health, guided by the GET2020 elimination roadmap, Eliminating Trachoma: Accelerating Towards 2020.[4]

"There are 157.7 million people in 43 countries who are at risk of trachoma."

The SAFE strategy brings additional benefits to communities: improving quality of life by preventing further vision loss with surgery, improving access to water, sanitation and hygiene practices and providing an annual dose of azithromycin that has been shown to reduce child mortality from malaria, diarrhoea and bacterial respiratory tract infections. Through the SAFE strategy, the trachoma community will continue to work with health and development communities to achieve equitable access to eye health care and universal health coverage for all.

References

1 www.who.int/blindness/causes/WHA51.11/en/

2 World Health Organization's Weekly Epidemiological Record published 29 June 2018, www.who.int/wer/2018/wer9326/en/

3 The updated WHO Alliance GET2020 epidemiological data sheet as of 17 April 2018: www.trachomacoalition.org/sites/default/files/content/resources/files/GET2020_2018_Global_Final.pdf

4 WHO Alliance for GET2020, Eliminating Trachoma: Accelerating Towards 2020, www.who.int/trachoma/news/News_Trachoma_Towards_2020/en/

Test your knowledge and understanding

This quiz is designed to help you test your own understanding of the concepts covered in this issue, and to reflect on what you have learnt.

TIM FRANSHAM/SIGHTSAVERS

It is important to see patients quickly in eye emergencies. INDIA

We hope that you will also discuss the questions with your colleagues and other members of the eye care team, perhaps in a journal club. To complete the activities online – and get instant feedback – please visit **www.cehjournal.org**

Question 1

In ophthalmic emergencies, which of the following statements are true? *Tick all that are true.*

- ☐ **a.** Dealing with emergencies is the ophthalmologist's responsibility and other members of staff should just follow instructions
- ☐ **b.** It is not helpful to practise for emergencies, because simulation is not like the real thing
- ☐ **c.** Eye emergencies must be referred to a specialist immediately
- ☐ **d.** Although uncommon, everyone encounters an ophthalmic emergency at some time

Question 2

A 60-year-old farmer attends your clinic complaining of rapid loss of vision and a painful red eye. On examination his vision is CF and the eye is red, but the lids are not swollen. Which of the following are possible diagnoses? *Tick all that are true.*

- ☐ **a.** Retinal detachment
- ☐ **b.** Acute glaucoma
- ☐ **c.** Microbial keratitis
- ☐ **d.** Orbital cellulitis
- ☐ **e.** Optic nerve compression

Question 3

Managing emergency infections: which of the following are true? *Tick all that are true.*

- ☐ **a.** Treatment of endophthalmitis should be delayed until you have identified the infectious organism
- ☐ **b.** Orbital cellulitis can be treated with intensive topical antibiotics
- ☐ **c.** The most severe form of ophthalmia neonatorum is caused by *Chlamydia trachomatis*
- ☐ **d.** Microbial keratitis should be treated with hourly broad-spectrum antibiotics

Question 4

Which immediate management protocol is best for the eye emergencies listed to the right?

a. Chemical burn	**i.** Intravenous antibiotics
b. Orbital cellulitis	**ii.** Eye shield
c. Acute glaucoma	**iii.** Anterior vitrectomy
d. Penetrating injury	**iv.** Intensive irrigation
e. Posterior capsule rupture	**v.** Hourly topical antibiotics
f. Microbial keratitis	**vi.** Acetazolamide 500 mg

ANSWERS

1. a. False. It is everyone's responsibility. b. False. Practice means one is more prepared and better able to manage the real emergency. c. False. Some emergencies require immediate intervention before referral. d. True. Most health workers will encounter an eye injury or other ocular emergency at some time.

2. a. False. Retinal detachment does not cause a red eye, although loss of vision may be sudden when the macula becomes detached. b. True. In acute glaucoma the eye will be painful, red and hard. Visual loss is due to associated corneal oedema. c. True. A corneal infection will cause a painful red eye with loss of vision due to an ulcerated cornea. d. False. Orbital cellulitis can cause a red eye and loss of vision but would also cause swollen eyelids and, often, proptosis. e. False. In optic nerve compression the onset of visual loss is usually slow and the eye remains white, but the globe may be proptosed and the eyelids swollen and tense.

3. a. False. Once cultures have been taken, treatment for endophthalmitis with broad spectrum antibiotics should start. The sooner intravitreal antibiotics are given, the more likely the eye will recover. b. False. Orbital cellulitis requires intravenous systemic antibiotics. c. False. It is caused by *Neisseria gonorrhoeae*. d. True

4. a. iv b. i c. vi. d. ii. e. iii. f. v

Picture quiz

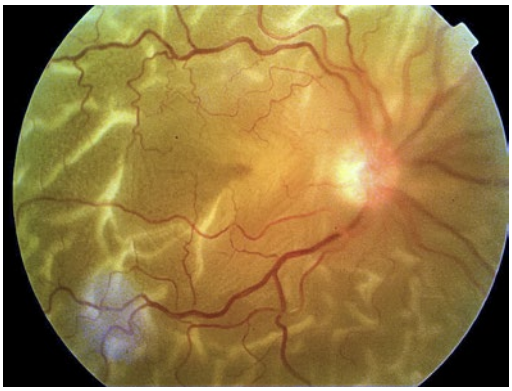

GARTNAVEL HOSPITAL

This is a fundus photo of a 60-year-old man, who had successful cataract surgery three years ago. His visual acuity is hand motions, and he complains of sudden, painless loss of vision in his right eye two weeks ago.

Tick ALL that are TRUE

Question 1 What is the most likely diagnosis?

- ☐ **a.** Optic atrophy
- ☐ **b.** Chronic open-angle glaucoma
- ☐ **c.** Posterior capsule opacification
- ☐ **d.** Retinal detachment
- ☐ **e.** Diabetic retinopathy

Question 2 What clinical signs can you see?

- ☐ **a.** Grey 'red reflex'
- ☐ **b.** Wrinkled and folded retina
- ☐ **c.** Swollen optic disc margins
- ☐ **d.** Retinal haemorrhages and exudates
- ☐ **e.** The normal choroidal blood vessels cannot be seen

Question 3 How should this patient be managed?

- ☐ **a.** Oral acetazolamide 500 mg immediately
- ☐ **b.** Immediate referral to a retinal surgeon
- ☐ **c.** Posterior capsulotomy
- ☐ **d.** Advice to stop smoking and abstain from alcohol
- ☐ **e.** Routine referral for laser treatment

ANSWERS

1) All false except d.

2) a., b. & e. are true. c. & d. are false. The disc margins are slightly blurred. This is because they are out of focus. The retina is detached, so it is in front of the disc, which means either the disc or the retina will be out of focus in fundus photos of a retinal detachment.

3) All false except b.

Emergency eye care

In the past, eye emergencies were often dealt with by the most junior members of the team. Now, there is a growing awareness that these emergencies are dealt with better when overseen by a more senior consultant. The British Emergency Eye Care Society was founded in 2013 to bring together practitioners who provide acute ophthalmology services in the UK to improve practice and promote excellence in patient care. To find out more, visit **www.beecs.co.uk**

IAPB Council of Members meeting 2018

IAPB

A total of 350 members of over 100 global and local eye health organisations recently met in India at the International Agency for the Prevention of Blindness (IAPB) Council of Members meeting in Hyderabad, India. On the agenda was Universal Health Coverage and eye health, technology, and partnerships in eye care. A round-up with videos and photos from the different meetings are available online at **http://bit.ly/CoM18RP**

Courses

MSc Public Health for Eye Care, London School of Hygiene & Tropical Medicine

Fully funded scholarships are available for Commonwealth country nationals. The course aims to provide eye health professionals with the public health knowledge and skills required to reduce blindness and visual disability. For more information visit **www.lshtm.ac.uk/study/masters/mscphec.html** or email **romulo.fabunan@lsthm.ac.uk**

Free online courses

The ICEH Open Education for eye care programme offers a series of online courses in key topics in public health eye care. All the courses are free to access and include: Global Blindness, Eliminating Trachoma, Ophthalmic Epidemiology: Basic Principles and Application to Eye Disease.

More free courses coming! Certification also available.

For more information visit **http://iceh.lshtm.ac.uk/oer/**

Subscriptions

Contact Anita Shah
admin@cehjournal.org

Subscribe to our mailing list
web@cehjournal.org or visit **www.cehjournal.org/subscribe**

Visit us online

www.cehjournal.org

www.facebook.com/CEHJournal

https://twitter.com/CEHJournal

Next issue

COLUMBUS OPHTHALMOLOGY ASSOCIATES, COMVISION.COM

The next issue of the *Community Eye Health Journal* is on the theme **complicated cataract surgery**

IN THIS ISSUE

Eye emergencies in this issue

First-line management of and preparation for the following eye emergencies are addressed in this issue of the *Community Eye Health Journal*.

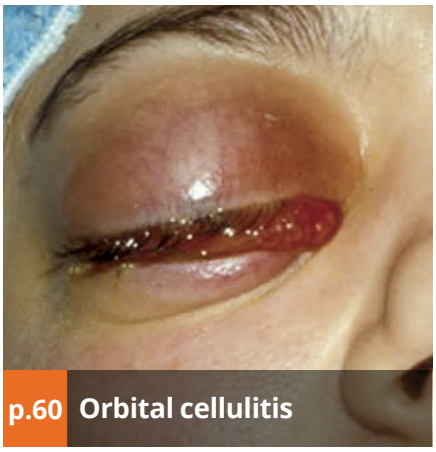

JAMES GARRITY, WWW.MSDMANUALS.COM

DR. T.S. OLULEYE, UNIVERSITY COLLEGE HOSPITAL, IBADAN, NIGERIA

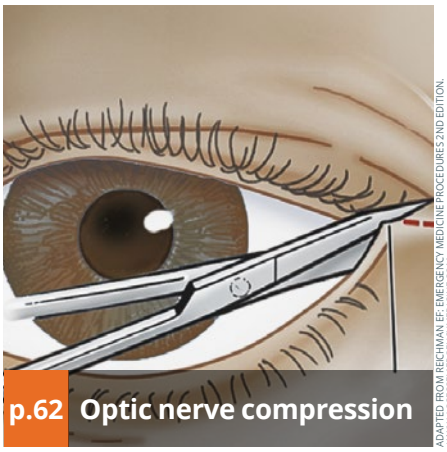

ADAPTED FROM REICHMAN EF: EMERGENCY MEDICINE PROCEDURES 2ND EDITION. WWW.ACCESSEMERGENCYMEDICINE.COM

GARTNAVEL HOSPITAL

N DU TOIT AND L VAN ZYL, 2013

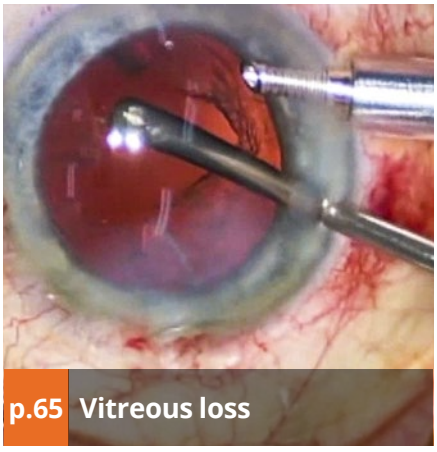

WILLIAM DEAN

SIMON ARUNGA

DAVID YORSTON

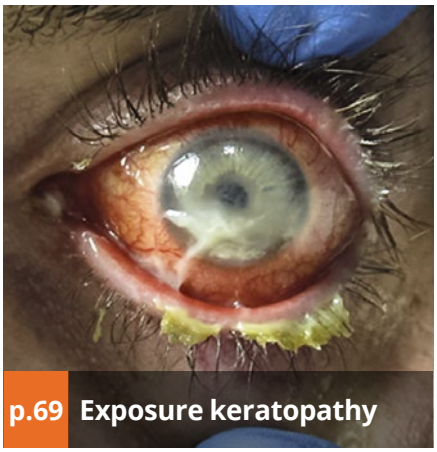

RISMA JM, SYED NA (2014)

HELEN KELLER INTERNATIONAL

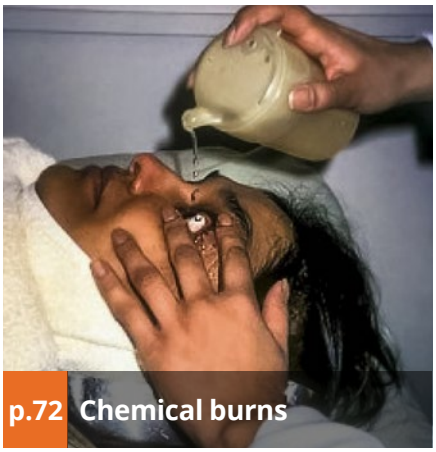

PAK SANG LEE