Community Eye Health JOURNAL

International Centre for Eye Health

VISION 2020 THE RIGHT TO SIGHT

VOLUME 21 | ISSUE 65 | MARCH 2008

Cataract complications

EDITORIAL

David Yorston
Consultant Ophthalmologist, Tennent Institute of Ophthalmology, Gartnavel Hospital, 1053 Great Western Road, Glasgow G12 0YN, Scotland.

Any eye surgeon, no matter how experienced, will occasionally encounter a serious cataract complication. Although complications may be devastating for the patient and are always distressing for the surgeon, are they really a major issue for VISION 2020? The evidence says that they are.

Impact

We know from numerous population-based surveys that a significant number of cataract operations may have poor outcomes (defined as presenting visual acuity of less than 6/60).

Poor outcomes are distressing or disappointing for patients. They reflect badly on the health or surgical facility and on the surgical team. Poor outcomes may also affect the sustainability of services; they discourage other patients from coming for surgery and make patients even more reluctant to contribute towards the cost of cataract operations.

In general, poor vision after cataract surgery is caused by: inadequate correction of post-operative refractive error (lack of **spectacles**); failure to detect pre-existing eye conditions, e.g. macular degeneration or amblyopia (**selection**); or surgical complications (**surgery**).

The widespread adoption of intraocular lenses is starting to decrease the number of patients left functionally blind after cataract surgery because they are not able to obtain the necessary aphakic correction spectacles.

Lance Bellers/CEH

Cataract surgery. ETHIOPIA

Problems of selection can be addressed by careful pre-operative evaluation, which should reduce the number of poor results due to the presence of other eye diseases. This will help to prevent complications.

Surgical complications, which are the main focus of this issue, can to some extent be prevented by good practice and surgical technique. When complications do occur, proper management is crucial to reduce the possibility of a poor outcome for the patient.

There are currently no comprehensive figures on the proportion of poor outcomes of cataract surgery in developing countries and on the relative importance of spectacles, selection, and surgery (Table 1, page 2, provides data from Bangladesh,[1] Kenya,[2] and Pakistan[3]). At a conservative estimate, at least 25% (or 1.5 million) of the six million cataract operations performed annually in developing countries will have

Editorial continues overleaf ➤

IN THIS ISSUE

Community Eye Health JOURNAL

Supporting VISION 2020: The Right to Sight

The journal is produced in collaboration with the World Health Organization

Volume 21 | Issue 65 | March 2008

Website
Back issues are available at:
www.cehjournal.org

Subscriptions
Community Eye Health Journal
International Centre for Eye Health
London School of Hygiene and Tropical Medicine,
Keppel Street, London WC1E 7HT, UK.
Tel +44 207 612 7964/72
Fax +44 207 958 8317
Email admin@cehjournal.org

The *Community Eye Health Journal* is published four times a year and sent **free to applicants from low- and middle-income countries**. French, Spanish, and Chinese translations are available and a special supplement is produced for India (in English). Please send details of your name, occupation, and postal address to the *Community Eye Health Journal*, at the address above. Subscription rates for applicants elsewhere: one year UK £50; three years UK £100. Send credit card details or an international cheque/banker's order made payable to London School of Hygiene and Tropical Medicine to the address above.

ISSN 0953-6833

Table 1. Causes of poor outcomes (presenting vision <6/60)

	Percentage of total number of operations leading to a poor outcome	Cause of poor outcomes		
		Spectacles	Selection	Surgery
Bangladesh	28%	37%	41%	22%
Kenya	22%	34%	36%	30%
Pakistan	34%	36%	39%	25%

poor outcomes. About one quarter of these poor outcomes are due to surgical complications. Over 375,000 people can therefore suffer permanent visual impairment every year as a result of surgical complications.

This means that surgical complications, and cataract complications in general, represent a significant obstacle to the success of any blindness prevention programme. The topics discussed in this issue are therefore vital to the successful implementation of VISION 2020.

Important complications

Many things can go wrong during or immediately after cataract surgery. It is impossible to address every single complication in one issue of the journal, so we have concentrated on those that we feel are important.

What is an important complication? Some complications are common, but their impact is relatively minor. Others are rare but have a devastating impact. The articles in this issue will focus primarily on capsular rupture and vitreous loss, which is relatively common and potentially serious, and on endophthalmitis, which is rare but devastating.

Does capsular rupture and vitreous loss matter? Even in well-equipped teaching hospitals in the United Kingdom, vitreous loss is associated with a nearly fourfold greater risk of a poor visual outcome.[4] In operating theatres without vitrectomy equipment, the risk of a poor outcome is likely to be even higher. However, not every patient who suffers capsular rupture and vitreous loss experiences a poor outcome. If the complication is managed well, it is possible to retain excellent vision (see article on page 6).

In high-income countries, the incidence of capsular rupture and vitreous loss appears to be declining and is now in the region of 1–2%. This improvement may be related to the use of phacoemulsification and to earlier intervention, which means that the great majority of cataracts are now removed before they are mature. In low- and middle-income countries, however, the incidence of capsular rupture and vitreous loss appears to be higher.[5] This is probably due to the greater complexity of many cataract operations in developing countries, rather than to specific deficiencies of training, expertise, or equipment used.

Vitreous loss also increases the risk of endophthalmitis, the most feared complication of intraocular surgery. The incidence of endophthalmitis may vary. Studies from Europe give the estimated incidence as 0.14%.[6] At Aravind Eye Hospital, in India, this incidence is about 0.05%.[7]

The causes of endophthalmitis might vary with geography. In most European studies, *Staphylococcus epidermidis* is the most common infecting microorganism. This bacterium is found in normal eyelid skin and conjunctiva, and it enters the eye during surgery. However, in South India, *Nocardia* species were the commonest cause of infection.[7] When endophthalmitis does occur, the prognosis is grim. In the UK, one third of patients who suffered this complication had a final visual acuity (VA) of less than 6/60, and 13% had lost all light perception.[6] At Aravind Eye Hospital in India, 65% of eyes had VA <6/60.[7] However, these figures also show that the prognosis following endophthalmitis is by no means hopeless.

Preventing complications

We know that certain eyes are more likely to suffer complications than others (see article on page 12). It is therefore very important to detect these conditions before surgery. For example, eyes with endothelial dystrophy (such as Fuch's dystrophy and corneal dystrophy), pseudoexfoliation, mature cataracts, or high ametropia (>6 dioptres of myopia or hypermetropia) are all at greater risk than eyes without these features. Simple scoring systems have been devised to stratify patients into low, medium, and high risk.[8]

It is important to collect data in order to identify patients at risk and to monitor their management before and after surgery. Even where the incidence of complications is low, regular collection of data helps to identify high-risk patients and to confirm that they are being managed appropriately. Monitoring of cataract surgical outcomes is associated with a reduction in the incidence of surgical complications.[9]

Some risk factors are intrinsic to the patient and, short of avoiding surgery altogether, very little can be done to eliminate them. However, in the event of surgery, high-risk cases should be operated on in an appropriate setting, by a surgeon who has the right level of experience. It has been shown that surgery carried out in eye camps, or by an inexperienced trainee, is more likely to result in complications than surgery undertaken in hospital by an experienced surgeon. Therefore, if patients with high-risk eyes are identified, they should be operated on by a fully trained surgeon, preferably in a base hospital.

Although intrinsic risk factors cannot be avoided, other factors which may increase the risk of surgical complications are related to the delivery of the surgery. These latter risks can, and should, be modified. Much can be done before and during surgery to reduce the rate of complications.

Meticulous sterilisation of all surgical instruments and fluids, and careful aseptic technique, are of course essential. Articles in this issue describe important steps to avoid complications during small incision cataract surgery (page 4) and how to reduce the risk of endophthalmitis (page 9). Recently, a large randomised clinical trial has shown a substantial reduction in the risk of endophthalmitis if 1 mg of cefuroxime is injected into the anterior chamber at the conclusion of surgery (see abstract and comment on page 11). This technique should be adopted universally, as it has the potential to save the sight of thousands of people per year.

'We should maintain a culture that values outcome as highly as output'

The importance of managing complications

With all complications, including capsular rupture and vitreous loss, and even endophthalmitis, the prognosis is better if the complication is managed effectively. Not every patient who suffers capsular rupture and vitreous loss experiences a poor outcome. If the complication is managed well, it is possible for the patient to retain excellent vision. However, we often do not deal with vitreous loss as well as we should. The article on page 6 provides top tips from experienced cataract surgeons for managing vitreous loss. In the case of endophthalmitis, early recognition and prompt treatment with intravitreal vancomycin and either ceftazidime or amikacin seems to offer the best hope of visual recovery. With immediate use of intravitreal antibiotics, some eyes will recover useful vision.

Because complications can and will occur, even in the best of cases, the eye care team must be prepared to manage them efficiently. Being prepared means: being trained to manage the problem; knowing where the relevant supplies are kept; having the right drugs and equipment on hand; and ensuring that the entire team is aware of the protocols for dealing with a complication. For example, there should be a protocol for vitrectomy in case of vitreous loss, and appropriate equipment should be on site. If phacoemulsification is being used, a protocol is needed to deal appropriately with dropped nuclei. When this complication is managed by prompt vitrectomy and fragmentation of the nucleus, the outcomes are normally good. However, if the nuclear material is not removed, the eye will be blinded by a combination of severe inflammation and glaucoma. No eye clinic should be using phacoemulsification unless they have identified a facility to which they can refer patients for vitrectomy and fragmentation of a retained nucleus. As phacoemulsification becomes more common in low- and middle-income countries, the number of dropped nuclei will also increase. Dislocation of fragments of the lens nucleus into the vitreous occurs in approximately 0.3% of phacoemulsification operations. The incidence may be higher in low- and middle-income countries, where dense cataracts and pseudoexfoliation are more common.[10]

The management of complications needs to be incorporated into training programmes. For example, management of vitreous loss, like every other surgical skill, can only be learnt by practicing under the supervision of a more experienced surgeon. However, although vitreous loss is most likely to occur while the surgeon is inexperienced, when it does occur, the trainer will usually take over. This means that, in some developed countries, ophthalmologists may do a few hundred cataract operations during their training, but will only manage vitreous loss two or three times.

Our training programmes rightly emphasise the avoidance of complications in cataract surgery. However, we need a greater emphasis on the correct management of these complications when they do occur, as they inevitably will. No trainee is truly competent to operate on cataract patients independently unless, for example, they are also competent in the management of vitreous loss.

Conclusion

In conclusion, the surgeon's first responsibility is to prevent complications. However, despite our best efforts, they will occur. Our next priority is to ensure that we are prepared to deal with these complications effectively so that our patients can obtain good vision, regardless of what went wrong during surgery. If we improve our management of complications, we can be certain that we will reduce the number of poor visual outcomes and disappointed cataract patients.

In striving to reach the goals of VISION 2020, we must be careful to maintain a culture that values outcome (the quality of cataract operations) as highly as output (the number of operations performed).

K Hennig

Skin cleaned with povidone-iodine (Betadine 10%) before a cataract operation. NEPAL

References

1 Bourne RR, Dineen BP, Ali SM, Huq DM, Johnson GJ. Outcomes of cataract surgery in Bangladesh: results from a population based nationwide survey. Br J Ophthalmol 2003;87: 813–9.
2 Mathenge W, Kuper H, Limburg H, Polack S, Onyango O, Nyaga G et al. Rapid assessment of avoidable blindness in Nakuru district, Kenya. Ophthalmology 2007;114: 599–605.
3 Bourne RRA, Dineen B, Jadoon MZ, Lee PA, Khan A, Johnson GJ, Foster A, Khan D. Outcomes of cataract surgery in Pakistan: results from the Pakistan National Blindness and Visual Impairment Survey. Br J Ophthalmol 2007;9(4): 420–6.
4 Ionides A, Minassian D, Tuft S. Visual outcome following posterior capsule rupture during cataract surgery. Br J Ophthalmol 2001;85: 222–4.
5 Kothari M, Thomas R, Parikh R, Braganza A, Kuriakose T, Muliyil J. The incidence of vitreous loss and visual outcome in patients undergoing cataract surgery in a teaching hospital. Indian J Ophthalmol 2003;51: 45–52.
6 Kamalarajah S, Silvestri G, Sharma N, Khan A, Foot B, Ling R et al. Surveillance of endophthalmitis following cataract surgery in the UK. Eye 2004;18: 580–7.
7 Lalitha P, Rajagopalan J, Prakash K, Ramasamy K, Prajna NV, Srinivasan M. Postcataract endophthalmitis in South India: incidence and outcome. Ophthalmology 2005;112: 1884–9.
8 Muhtaseb M, Kalhoro A, Ionides A. A system for preoperative stratification of cataract patients according to risk of intraoperative complications: a prospective analysis of 1,441 cases. Br J Ophthalmol 2004;88: 1242–6.
9 Limburg H, Foster A, Gilbert C, Johnson GJ, Kyndt M, Myatt M. Routine monitoring of visual outcome of cataract surgery. Part 2: Results from eight study centres. Br J Ophthalmol 2005;89: 50–2.
10 Gogate PM, Kulkarni SR, Krishnaiah S, Deshpande RD, Joshi SA, Palimkar A et al. Safety and efficacy of phacoemulsification compared with manual small-incision cataract surgery by a randomized controlled clinical trial: six-week results. Ophthalmology 2005;112: 869–74.



Small incision cataract surgery: tips for avoiding surgical complications

Reeta Gurung
Deputy Medical Director, Tilganga Eye Centre, Kathmandu, Nepal.
Email: reetagurung@gmail.com

Albrecht Hennig
Programme Director, Eastern Regional Eye Care Programme, Lahan, Nepal.
Email: akhennig@gmx.net

Small incision cataract surgery (SICS) is one of the cataract surgical techniques commonly used in developing countries. This technique usually results in a good visual outcome and is useful for high-volume cataract surgery.[1–3]

This article describes how to minimise surgical complications in SICS.

Before you begin

Nuwan Niyadurupola

Figure 1. Instilling povidone-iodine (Betadine) 5% eye drops

K Hennig

Figure 2. Skin around the eye cleaned with povidone-iodine (Betadine) 10%

Before you begin

With SICS, as with all cataract surgery techniques, it is mandatory to perform a thorough preoperative assessment of the patient (see article on page 12). This will allow the surgeon to prepare for anticipated complications – for example, a dislocated or subluxated lens – and to plan the operation accordingly.

Prepare the patient in the following way:

- Wash the patient's face.
- Instil povidone-iodine (Betadine) 5% aqueous eye drops (Figure 1).
- Clean the skin around the eye with povidone-iodine 10% (Figure 2).

Other measures will also help to reduce the risk of postoperative endophthalmitis: proper hand washing (see 'how to' article on page 17), the use of sterile instruments, the 'non-touch' technique, the subconjunctival injection of antibiotics,[4,5] and the intracameral injection of cefuroxime[6] at the end of surgery (see article on page 11). The dose of intracameral cefuroxime must be meticulously prepared, as no commercially made preparation is available (see box on page 11).

Tunnel construction

Tunnel size

The expected size and density of the nucleus should determine the size of the tunnel. For example, the extraction of immature cataracts in younger patients may only require a small tunnel, just large enough for the intraocular lens (IOL) optic to pass through. Very big, brown nuclei require a larger tunnel size. These nuclei can sometimes be up to 8 mm in diameter and 4 mm thick. However, a large tunnel need not be a problem: even larger tunnels are self-sealing and don't need suturing if they are prepared correctly. If there is doubt about the self-sealing effect, the surgeon may apply one or two sutures at the end of surgery. If correctly tied, these will, at the same time, reduce any induced astigmatism.

Constructing the tunnel

- Only a correct sclerocorneal tunnel incision, at least 1 to 2 mm into the clear cornea, leads to a self-sealing wound.
- Scleral cauterisation before tunnel. construction reduces the risk of pre- and postoperative hyphaema.
- Sharp tunnel instruments (such as the crescent knife and keratome) should be used to construct the tunnel. A blunt keratome could cause stripping of Descemet's membrane.
- Stabilising the sclera with toothed forceps makes tunnel construction easier (Figure 3). However, in order to avoid tunnel damage and leakage, the forceps should not be used on the tunnel flap.
- With a half-thickness sclerocorneal tunnel incision, the direction of the crescent knife should always be parallel to the sclerocorneal plane.
- Judge the depth of half-thickness sclerocorneal tunnel incisions by observing how clearly you can see the crescent knife during the incision (Figure 4). If the crescent knife can be seen very clearly, this indicates that the scleral layer is very thin and that the crescent knife might perforate to the outside. (causing what is known as a 'buttonhole')
- A buttonhole can be corrected by making a deeper 'frown' incision and dissecting the tunnel in a deeper plane, starting at the opposite side of the buttonhole.[7]
- If the crescent knife is not visible during the incision, this indicates that you are working too deeply inside the sclera; you may perforate towards the anterior chamber's angle (a 'premature entry').
- A premature entry could lead to surgical complications, such as iris trauma or iridodialysis, iris prolapse, and a tunnel which is not self-sealing.
- Manage a premature entry by starting a more shallow dissection at the other end of the tunnel. Suturing of the wound is required at the end of surgery.[7]

Opening of the anterior capsule

This can be done by different techniques (such as linear capsulotomy (Figure 5), the 'can-opener' technique, and triangular or V-shaped capsulotomy) or by capsulorhexis.

Capsulotomies are easy to perform, but may lead to uncontrolled capsular tear extension, posterior capsule rupture, vitreous loss, and IOL decentration. These problems can be avoided by a careful hydrodissection, especially in patients with posterior polar cataract or posterior lenticonus (hydrodissection is most effective if the fluid is injected directly into the capsule[7]). Keeping instrument manipulation to a minimum during surgery will also help you to avoid posterior capsule rupture.

The best capsular opening is a continuous curvilinear capsulorhexis (CCC):

Tunnel construction

K Hennig

Figure 3. Stabilising the sclera with toothed forceps

K Hennig

Figure 4. Making the sclerocorneal tunnel incision

Opening of the anterior capsule

K Hennig

Figure 5. Linear capsulotomy

Figure 6. Continuous curvilinear capsulorhexis

K Hennig

it will guarantee a long-term, 'in the bag' IOL centration (Figure 6). However, CCC is more difficult to learn. This technique sometimes requires staining of the capsule and the opening also needs to be large enough for the nucleus to get through. It may therefore not be possible to use this technique in eyes with very big nuclei and smaller pupils. In such a situation, a linear, triangular, or other capsulotomy may be preferred.

Failing to complete the anterior capsulotomy, making a too-small CCC, and pulling residual anterior capsular tags can cause the posterior capsule to rupture. Early recognition and correction of these problems is very important to avoid further complications.

Nucleus removal

During SICS, different techniques can be used to remove the nucleus: either hydro-expression alone (using an anterior chamber maintainer), hydroexpression plus extraction (using an irrigating vectis or Simcoe cannula), or extraction alone (using a 'fishhook' needle). Problems with these different SICS techniques are mainly related to the size of the tunnel and the proximity of the nucleus to the corneal endothelium.

Difficulties with nucleus delivery are mostly due to the inner tunnel opening being too small. This should be checked before nucleus removal, e.g. with the visco cannula (Figure 7). If there is any doubt about the correct tunnel size, it is better to further enlarge the tunnel before removing the nucleus. However, the surgeon should avoid cutting into the anterior chamber's angle while enlarging the inner tunnel opening, as this carries an increased risk of hyphaema.

While lifting the nucleus into the anterior chamber (Figure 8), special care is required in patients with pseudoexfoliation and in older patients with weak zonules.

While delivering the nucleus through the tunnel, accidental contact between the nucleus and the corneal endothelium must be avoided. Otherwise, postoperative corneal oedema, and sometimes even corneal decompensation, may occur.

In order to avoid such corneal problems, you must inject sufficient viscoelastic fluid between the lens and the cornea to protect the endothelium. Instruments for nucleus removal, such as the irrigating vectis, Simcoe cannula, or fishhook, should be kept away from the cornea and should not push the nucleus against the cornea during nucleus delivery.These instruments should push slightly posteriorly, which will help to open the incision for easier nucleus delivery (Figures 9 & 10). In addition, gently pulling the bridle suture makes nucleus delivery through the tunnel easier.

Removal of the cortex

Most of the lens cortex can be removed with a Simcoe cannula through the tunnel (Figure 11). A sub-incisional cortex can be safely aspirated through a side port at 130–180° from the incision site.[8] If stripping of Descemet's membrane occurs while cleaning the cortex, great care should be taken not to tear it off. If this happens, air should be injected into the chamber at the end of the operation to push Descemet's membrane against the cornea.

While clearing the cortex with a Simcoe cannula, posterior capsule rupture and vitreous loss may occur. This can be avoided by carefully watching the posterior capsule. Wrinkles indicate that the posterior capsule is caught in the aspiration port of the Simcoe cannula. This requires immediate back-flushing to avoid posterior capsular rupture.

To reduce the risk of a postoperative increase in intraocular pressure, thorough removal of viscoelastics is required.

Removal of the cortex

K Hennig

Figure 11. Removing the cortex using a Simcoe cannula

Nucleus removal

K Hennig

Figure 7. Checking the tunnel size

Figure 8. Mobilising the nucleus before lifting it into the anterior chamber

K Hennig

Figure 9. Inserting the fishhook needle

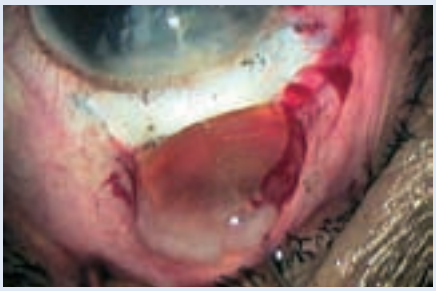

Figure 10. Delivering the nucleus

K Hennig

References

1 Hennig A, Kumar J, Yorston D, Foster A. Sutureless cataract surgery with nucleus extraction: outcome of a prospective study in Nepal. Br J Ophthalmol 2003;87: 266–270.

2 Hennig A et al., World Sight Day and cataract blindness. Br J Ophthalmol 2002;86: 830–31.

3 Ruit SPG, Gurung R, Tabin G, Moran D, Brian G. An innovation in developing world cataract surgery. Clin Exp Ophthalmol 2000;28: 274–279.

4 Ng JQ, Morlet N, Bulsara MK, Semmens JB. Reducing the risk for endophthalmitis after cataract surgery: population-based nested case-control study: endophthalmitis population study of western Australia sixth report. J Cataract Refract Surg 2007;33(2): 269–80.

5 Kamalrajah S, Ling R, Silvestri G, Sharma NK, Cole MD, Cran G, Best RM. Presumed infectious endophthalmitis following cataract surgery in the UK: a case-control study of risk factors. Eye 2007;21(5): 580–6.

6 ESCRS Endophthalmitis Study Group. Prophylaxis of postoperative endophthalmitis following cataract surgery: results of the ESCRS multicenter study and identification of risk factors. J Cataract Refract Surg 2007;33(6): 978–88.

7 Schroeder B. Sutureless cataract extraction: complications and management; learning curves. Comm Eye Health J 2003;16(48): 58–60.

8 Traianidis P, Sakkias G, Avramides S. Prevention and management of posterior capsule rupture. Eur J Ophthalmol 1996;6(4):379–82.

Management of capsular rupture and vitreous loss in cataract surgery


Nick Astbury
Consultant Ophthalmic Surgeon, Norfolk and Norwich University Hospital NHS Trust, Colney Lane, Norwich NR4 7UY, UK.

Every eye surgeon has experienced – or will experience – that sinking feeling when the posterior capsule is ruptured and vitreous comes forward into the anterior chamber. At that moment everything changes, including the heart rate of the surgeon and the possible outcome for the patient.

But all is not lost. If the theatre team are well prepared, the situation can be managed calmly and professionally in order to achieve the best possible visual result.

It is most important to remove every trace of vitreous from the wound and anterior chamber. Failure to achieve this increases the risks of leakage, of infection due to a vitreous wick, or of vitreous traction that may lead to cystoid macular oedema or retinal detachment.

In an ideal world, automated vitrectomy should be the procedure of choice to deal with vitreous loss; however, if the equipment is unavailable, it may be necessary to resort to the 'sponge and scissors' vitrectomy method.

Implanting an intraocular lens (IOL), although desirable, should not be undertaken at any cost if it will involve further trauma to the eye.

It is worth mentioning that pressure from the speculum is often to blame for the difficulty surgeons experience in dealing with capsular rupture and vitreous loss. Therefore, it is always advisable to make sure that the speculum is not pressing on the eye.

Below, five ophthalmologists from around the world present their tips on managing this complication. Their opinions and methods differ, depending upon individual circumstances and available resources.

Kasturba Hospital

Vitrectomy parameters set on a phaco machine used to perform automated vitrectomy after capsular rupture and vitreous loss. INDIA

Kasturba Hospital

A surgeon performs a vitrectomy after capsular rupture and vitreous loss. INDIA

Tanzania


Mark Wood
Consultant Ophthalmologist, CCBRT Hospital, Box 23310, Dar es Salaam, Tanzania.
Email: **markwood@cats-net.com**

Capsular rupture is a dreaded complication of cataract surgery; it jeopardises the chances of inserting a posterior lens and therefore obtaining the ideal optical correction of the patient's aphakia after the operation. However, if this complication does occur, do not panic: most cases can be salvaged.

Tip 1

Stop everything. Sit back and **think**. Get your vitrector ready while thinking. The Guerder Vitron anterior vitrectomy machine is ideal and should be made available to all cataract surgeons. You will have to perform an **anterior vitrectomy**. Try to preserve as much capsule as possible while you do this.

Tip 2

After you have done a vitrectomy, if you are not sure how much capsule remains it may be wise to close the incision and consider implanting a **secondary IOL**. Later, you can use the slit lamp to visualise the remaining capsule and plan your operation.

Tip 3

If you have done a continuous curvilinear capsulorhexis, you should be able to **insert a lens in the sulcus**, as the anterior rim of the capsule will hopefully still be there. With a linear capsulotomy this may be possible as well. I usually insert a hard lens into the sulcus and abandon any idea of using a foldable lens. If there is enough capsule inferiorly, I use an Aurolab scleral fixation lens. This IOL has the advantage of having a large optic of 6.5 mm which gives it added stability; it can be sutured with 10-0 Prolene to the iris at the 12 o'clock position through the hole in the haptic. This is not possible with small incision surgery, because you cannot suture the lens to the iris down a tunnel incision.

Tip 4

If you have done small incision surgery, it is more difficult to manage vitreous loss. In this circumstance, I would probably close the eye and implant a secondary IOL. It is always preferable to implant a posterior lens. However, if this is not possible, an anterior chamber lens is a good alternative. Do not forget to do an **iridectomy**. I perform two iridectomies when placing an anterior lens.

Tip 5

In a patient with an only eye, do not forget that +10 **aphakic correction spectacles** can give good vision; this is better than struggling to insert an imperfect IOL which may cause more damage to the tissues.

India

Uday Gajiwala (left), Rajesh Patel, and others in the Sewa Rural Team

Sewa Rural, Jhagadia District, Bharuch, Gujarat 393 110, India.

Tip 1

If capsular rupture and vitreous loss occurs after complete removal of the lens matter, perform a good anterior vitrectomy (an automated vitrectomy probe without in-built irrigation is preferable).

To prevent extension of the tear, hydration of the vitreous, and flushing of the vitreous, **the cut rate of the vitrectomy machine should be high** (up to 800 cuts per minute) and **the vacuum should be low** (approximately 50 mmHg).

Tip 2

If capsular rupture and vitreous loss occurs while some lens matter remains, perform a good automated **anterior vitrectomy and cortex removal**, ensuring aspiration of the cortex towards the tear and not away from it. Dry aspiration is most suitable.

Tip 3

Complete removal of vitreous from the anterior chamber is indicated by a round pupil, the falling back of the iris, and the formation of a single air bubble after air injection.

Tip 4

Special situations

- If the capsular tear is in the inferior position, be careful because the IOL can drop from the tear into the vitreous cavity.
- If there is a bulge in the vitreous material, giving a systemic injection of mannitol while the patient is on the operating table may help to reduce the pressure.

Tip 5

Placement of the IOL

In the case of a posterior capsular tear involving less than a third of the periphery, the IOL can be placed with the haptics positioned away from the tear; the stability of the IOL should then be checked.

With a central tear and an adequate rim all the way around, a sulcus-fixated IOL can be implanted. The IOL can be placed in front of the anterior capsule if the rhexis is round and the rim is adequate in size. But if the support is less than adequate, it may be necessary to place an anterior chamber IOL or a sclerally fixated IOL.

In all cases of posterior capsular tear, it is important to use an IOL with a large optic size (>6.0 mm) and with a large overall diameter (>13.5 mm).

Always remember:

- The importance of recognising the complication as early as possible cannot be overemphasised.
- Do not panic, keep calm, keep to the basic rules.
- No vitreous should be left in the iris plane or in front of it.
- 'Sponge and scissors' vitrectomy should be avoided if at all possible.
- The placement of the IOL depends on the capsular support available – even if the anterior capsule is available, a posterior chamber IOL can be implanted in the sulcus.
- Try to do a primary IOL implant, whether it is an anterior chamber IOL or a sclerally fixated IOL.
- It is good practice to inform the patient of the complication.

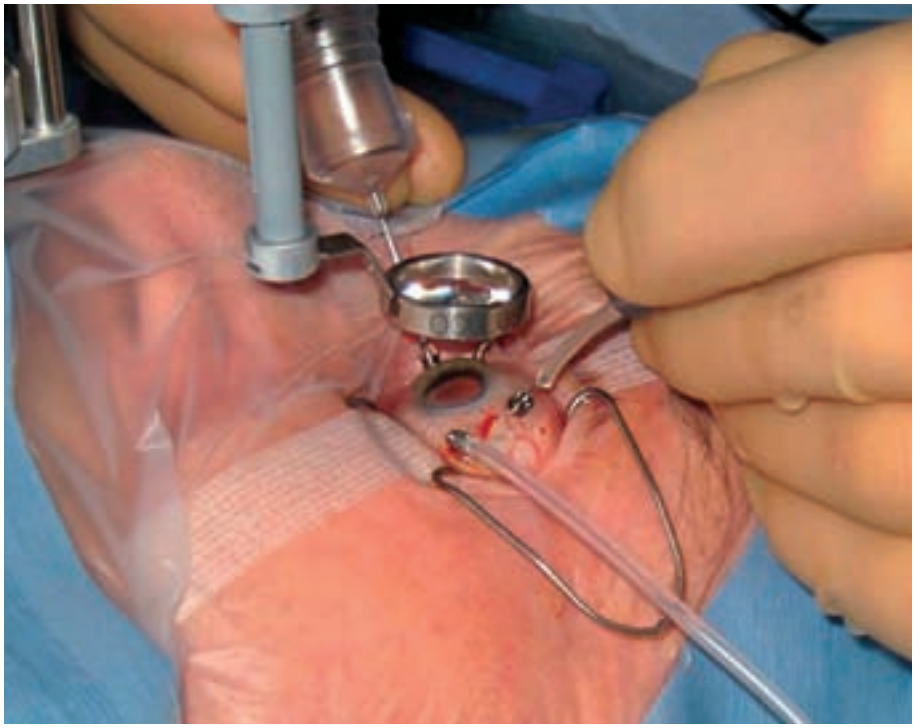

Nuwan Niyadurupola

Performing a three-port pars plana vitrectomy. UK

China

Yi Chen
People Eye Centre, Peking University People's Hospital, Beijing 100044, China.
Email: **chenyi88888@vip.sina.com**

Tip 1

Stop working as soon as you sense that there is a problem. Carefully remove the instrument from the eye if possible. Remember that an abrupt shallowing of the anterior chamber may extend the tear and that abrupt removal of the instrument may lead to lens material falling into the vitreous. **Inject visco-elastic fluid** through the side-port incision, if necessary, before removing instruments from the eye.

Tip 2

Maintain the anterior chamber and **stabilise the remaining lens material**. Filling the anterior chamber with viscoelastic helps to maintain the anterior chamber and may help to tamponade the anterior hyaloid face. Injecting viscoelastic below the remaining lens material may stabilise it.

Tip 3

If possible, **remove all remaining lens material**. Enlarge the incision and extract the nucleus with a loop. If the capsular rupture is small, the irrigation-aspiration technique may be used to aspirate the remaining cortex. If the capsular rupture is large and cortex is mixed with vitreous, an anterior vitrectomy may be used to remove both the cortex and vitreous.

Tip 4

If vitreous loss has occurred, remove all vitreous from the anterior chamber and the incision. A 'sponge and scissors' vitrectomy can be very useful if automated vitrectomy instruments are not available; however, it is unlikely to remove all vitreous from the anterior chamber. **Automated vitrectomy is preferable**.

Tip 5

Implant the IOL according to the situation. 'In the bag' placement is ideal. If there is a large rupture of the posterior capsule, the surgeon may implant the IOL in the ciliary sulcus. Once the IOL has been placed, gradually instil a miotic. Afterwards, remove the viscoelastic with **irrigation-aspiration**. Raising the irrigation bottle is important to avoid any shallowing of the anterior chamber; this will help prevent further vitreous prolapse. You must pay careful attention. In particular, check the pupil and wounds to ensure that all vitreous has been removed. Always check that the wounds are watertight.

Continues overleaf ➤

United Kingdom

Larry Benjamin
Consultant Ophthalmic Surgeon,
Department of Ophthalmology,
Stoke Mandeville Hospital,
Mandeville Road, Aylesbury, Buckinghamshire,
HP21 8AL, UK.

Tip 1
If vitreous loss is managed well, the outcome can be just as good as if it had not happened. The first tip is **early recognition** that vitreous loss has taken place. The implications of vitreous loss may vary, depending on the type of cataract surgery. It tends to be a fairly expulsive event when it occurs during extracapsular surgery, but it is less so during closed-chamber phacoemulsification. By recognising the event early, steps can be taken to minimise further problems. Take time to sit back for a minute and assess the situation carefully. Do not suddenly pull instruments out of the eye – this may cause vitreoretinal traction.

Tip 2
Keep calm and ask for the vitrector in a quiet, level voice (as if you were simply asking someone to pass the salt). Make sure the team environment stays calm and supportive. You should learn how to set up and use the vitrector before a case of vitreous loss has to be dealt with. This experience can be gained in a skills centre.

Tip 3
Use triamcinolone acetonide (Kenelog) to **stain the vitreous** in the anterior chamber (this is an off-label use). A solution of 40 mg in 1 ml can be used for this purpose, neat or diluted twice or three times its own volume with a balanced salt solution. A gentle injection of the drug via a Rycroft cannula into the anterior chamber (Figure 1) will make the vitreous easier to see and help to guide you: you will be able to see when all the vitreous has been removed from the wound and pupillary area (Figure 2). If some triamcinolone remains in the eye, it will have anti-inflammatory properties; however, checks should be made postoperatively for a rise in intraocular pressure.

Tip 4
Using a **separate small wound** for the vitrector prevents the main wound from becoming oedematous and maintains an effective closed chamber. Use the vitrector at the maximum cut rate (usually around 400 cuts per minute on an anterior vitrector) and make small movements of the probe within the eye. This will minimise vitreoretinal traction during the operation. It is a good idea to separate the infusion fluid from the vitrector and to start the anterior vitrectomy with no fluid running. Keep the vacuum low during this step. When the infusion is started, keep the flow rate low. An anterior chamber maintainer is a very useful device for delivering the infusion fluid. This is placed at the limbus and is self-retaining.

Figure 1. Triamcinolone acetonide is injected into the anterior chamber to stain the vitreous and make it easier to see.

Figure 2. Using a vitrector. Note the vitreous which has been stained with triamcinolone acetonide.

Tom Oetting and Medrounds Publications – www.medrounds.org/cataract-surgery-greenhorns (both)

Tip 5
Postoperative follow-up is important. The patient will need to be told that a complication has occurred and should be informed of the possible outcomes. A topical steroid, an antibiotic, and a mydriatic should be used postoperatively and regular follow-up visits should take place until the eye is quiet and further complications are ruled out or managed. If you did not place an implant during the initial operation, you can make arrangements to do this at a later date. Other forms of visual correction in the short term (such as contact lenses) can be discussed. You should carefully inspect the retinal periphery when the eye is quiet. The patient should be warned about the possible symptoms of retinal detachment, cystoid macular oedema, and infection.

> **'You should learn to set up and use a vitrector before a case of vitreous loss has to be dealt with'**

Nigeria

Sunday O Abuh
Paediatric Ophthalmologist, ECWA Eye Hospital, PO Box 14, Kano, Nigeria.
Email: **absund@yahoo.com**

Tip 1
Vitreous loss may be inevitable in eyes that have undergone **couching** or in cases of **vitreous degeneration**. However, in all cases, vitreous loss must be carefully managed to prevent complications such as defective wound closure, high astigmatism, high or low intraocular pressure, corneal oedema from endothelial touch, retinal detachment, chronic inflammation, or cystoid macular oedema.

Tip 2
Management starts with good **preoperative patient education** to reduce the risk of patient movement during surgery. Approximately 90–95% of our patients remain quiet during surgery without any form of premedication.

Tip 3
Poor anaesthesia is a major contributing factor to vitreous loss. **Good anaesthesia** must achieve good pain relief (analgesia) and immobilisation (akinesia) of the lids and globe (page 14).

Tip 4
Avoid undue pressure on the eye from the fixation forceps, speculum, or lens expressor. Avoid clumsy use of instruments inside the eye. Avoid creating too high a pressure when injecting the irrigating fluid into the anterior chamber.

Tip 5
When forced to use the manual 'sponge and scissors' vitrectomy method:

- Work with good magnification and illumination.
- Use non-fragmenting cellulose sponges.
- Touch the vitreous in the anterior chamber with a sponge tip and cut the vitreous strands with sharp De Wecker's or Wescott's scissors.
- Avoid excessive traction on the vitreous.
- Repeat the procedure until all strands of vitreous are removed from the anterior chamber, iris surface, and wound edges.
- After removing the vitreous, sweep the iris surface with an iris repositor to check whether there is residual vitreous. If present, the pupil may be distorted. Repeat the procedure until the pupil becomes round.
- A weak solution of pilocarpine (we use four drops of 4% pilocarpine in 2 ml of normal saline solution) may be instilled into the anterior chamber to constrict the pupil and keep the vitreous behind the iris.
- Re-form the anterior chamber with air after wound closure to minimise vitreous entrapment in the wound.

Endophthalmitis: controlling infection before and after cataract surgery

Nuwan Niyadurupola
Specialist Registrar in Ophthalmology, Department of Ophthalmology, Norfolk and Norwich University Hospital NHS Trust, Colney Lane, Norwich NR4 7UY, UK.
Email: nuwan.niya@doctors.org.uk

Nick Astbury
Consultant Ophthalmic Surgeon, Norfolk and Norwich University Hospital NHS Trust.

Endophthalmitis is a rare, but serious, postoperative complication of cataract surgery. It can have a devastating consequence on a patient's vision: some patients may lose all light perception.

The incidence of endophthalmitis has been reported to be between 0.13% and 0.7%.[1] The primary source of this intraocular infection is considered to be bacteria from the patient's ocular surface (cornea, conjunctiva) or adnexa (lacrimal glands, eyelids, and extraocular muscles).[2] The bacteria most frequently isolated are gram-positive coagulase-negative cocci (mainly *Staphylococcus epidermidis*) which account for 70% of culture-positive cases.[2] *Staphylococcus aureus* is isolated in 10% of culture-positive cases, *Streptococcus* species in 9%, *Enterococcus* species in 2%, and other gram-positive species in 3% of cases.[1] Gram-negative bacteria account for just 6% of culture-positive cases; however, an infection with these bacteria, particularly with *Pseudomonas aeruginosa*, can lead to a devastating visual outcome.[1,3]

Preoperative risk factors

Conditions that **increase the presence of bacteria on the ocular surface** are risk factors for the development of endophthalmitis.[1] These conditions include: blepharitis, conjunctivitis, cannuliculitis, lacrimal duct obstruction, contact lens wear, and an ocular prosthesis in the fellow orbit.

Eyelid abnormalities, particularly the presence of entropion, also increase the risk of endophthalmitis. The correction or treatment of these risk factors prior to cataract surgery is desirable to reduce the risk of infection.

Recent immunosuppressive treatment and a history of immunosuppression have also been shown to be significant risk factors for endophthalmitis.[4]

Tips for preventing endophthalmitis

- Instil povidone-iodine 5% eye drops prior to surgery.
- Carefully drape the eyelid and lashes prior to surgery.
- Use sterile gloves, gowns, and face masks.
- Construct watertight incisions, preferably three-plane.
- Manage complications (e.g. capsular rupture) effectively.
- Acrylic optics are better than silicone.
- Inject intracameral cefuroxime postoperatively (1 mg in 0.1 ml normal saline).

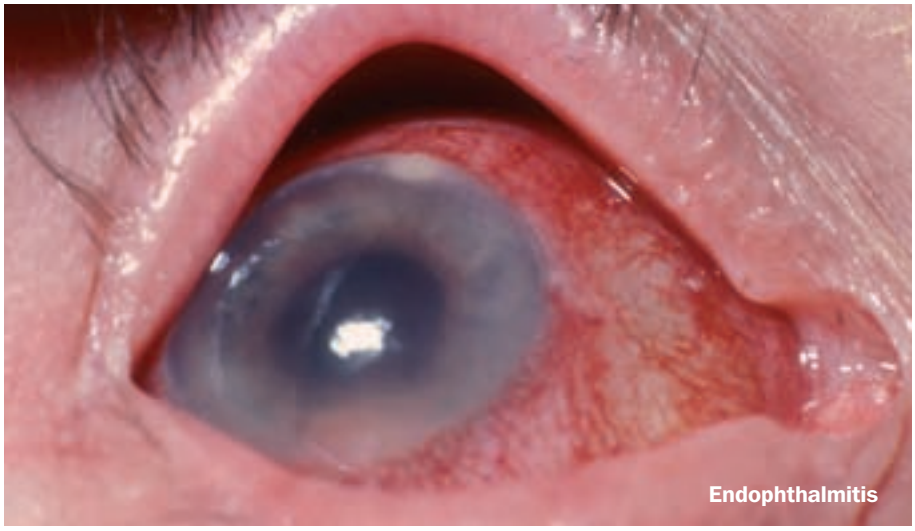

Nick Astbury

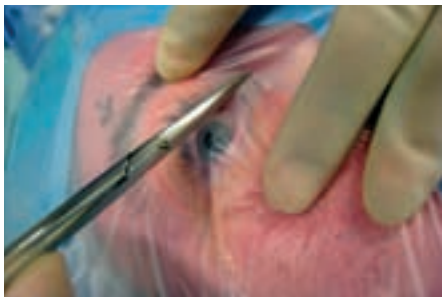

Nick Astbury

Figure 1. Preparation of the drape covering the eyelid and lashes prior to cataract surgery

Preparation of the patient

The meticulous preparation of the patient for cataract surgery is possibly the most important factor in reducing the risk of endophthalmitis. It has been found that the **instillation of topical 5% povidone-iodine** (Betadine) into the conjunctival sac prior to surgery significantly reduces the risk of endophthalmitis; this has become accepted preoperative practice.[2,4] The antimicrobial effect of povidone-iodine occurs within one minute of irrigation; it kills 96.7% of bacteria and lasts for at least one hour.[5] Povidone-iodine appears to be more effective in reducing infection than preoperative antibiotics.[1,2] As the bacteria responsible for endophthalmitis most commonly originate from the patient's eyelids, **careful draping of the eyelid and lashes** (Figure 1) is important in reducing the presence of bacteria in the surgical field, which in turn reduces the risk of endophthalmitis.[1,2] The practice of trimming lashes is not recommended: it does not reduce periocular bacterial flora and does not reduce the risk of endophthalmitis.[5]

Preparation of the surgeon

Proper **hand washing** (see page 17), followed by the use of **sterile gloves and gowns** during surgery, is accepted practice. However, there has been considerable discussion about the use of surgical masks. During a study in which culture plates were placed in the operative field, the wearing of surgical face masks was shown to significantly reduce bacterial cell counts.[6] However, other studies have found that the use of face masks produces no reduction in airborne bacteria in theatre and no reduction in wound infection rates in general surgery.[6] Other arguments for not wearing facemasks include: face masks increase condensation on operating microscopes, which may impair the surgeon's view; they may possibly cause rubbing off of facial skin squames into the operative field; and they impair communication.[6] However, a recent case-control study showed that the use of face masks by the surgeon and the scrub nurse significantly reduced the risk of endophthalmitis ($p<0.001$).[4] In conclusion, given the devastating consequences of endophthalmitis, the wearing of face masks is recommended.[7]

Note: Facemasks must be worn correctly; they must cover the nose, mouth, and chin completely and must never hang around the neck.

Surgical technique and intraoperative factors

Incisions

The clear corneal incisions commonly used for phacoemulsification are associated with a significantly increased risk of endophthalmitis, compared to **scleral tunnel incisions**.[2,8] This may relate to differences in wound healing and potential wound leaks. The incidence of a flat anterior chamber is higher with clear corneal incisions than with

Continues overleaf ➤

scleral tunnel incisions.[2] Temporal clear corneal incisions take longer to heal than scleral tunnel incisions and are also prone to fish-mouthing and trauma, thereby allowing access of bacteria into the eye.[2]

The construction of a **watertight corneal incision** is important in reducing the risk of intraocular infection. Straight-in and two-plane clear corneal incisions can leak; **three-plane incisions are better**.[2] Starting the incision in the **vascular region of the limbus** results in an increased fibroblastic response, which may promote healing.[2] Longer corneal incisions, in comparison to the incision width, are more stable than shorter length incisions and hence may reduce wound leaks and the risk of endophthalmitis.[2,9]

Complications

Surgical complications, in particular a torn posterior lens capsule, can significantly increase the risk of endophthalmitis.[4,8] This is backed up by animal studies. In one study on monkey eyes, the posterior capsule was shown to have a barrier effect against the development of endophthalmitis following the inoculation of bacteria into the anterior chamber.[4] In another study, bacteria injected into the vitreous of rabbit eyes more readily caused endophthalmitis than bacteria injected into the anterior chamber.[4] The association of endophthalmitis with surgical complications may explain the finding that cases of endophthalmitis are more prevalent when senior surgeons operate, as these surgeons may take on more technically difficult cases.[4,8]

Intraocular lenses

The choice of intraocular lens (IOL) can affect the risk of endophthalmitis. The use of IOLs with silicone optics is associated with an increased risk of endophthalmitis, compared with that of IOLs with **acrylic optics**. It is unlikely that this is due to the hydrophobic nature of silicone, since a comparison of hydrophobic and hydrophilic lenses showed no difference in the rates of endophthalmitis. The difference is more likely explained by the interaction of biofilms with the surface of the lens.[8] The material used for the IOL haptic and the type of IOL (multipiece or one-piece) did not seem to affect the incidence of endophthalmitis.[8] The use of injectable IOLs has been linked with a reduced risk of endophthalmitis, possibly as a result of the IOL not coming in contact with the tear film. However, there is often a strong correlation between the type of IOL insertion (forceps or injector) and the site of incision (scleral tunnel or clear corneal); it is considered that it is the site of incision that is the more important risk factor.[8]

Antibiotics

There is little evidence that using antibiotics in irrigating fluid during surgery can reduce the risk of endophthalmitis. Vancomycin is the antibiotic most commonly used in irrigating fluid, due to its activity against gram-positive bacteria. However, the half-life of vancomycin in the anterior chamber is less than two hours and, for the most common gram-positive bacteria, it does not achieve concentrations in the anterior chamber above MIC90 (the concentration of the antibiotic at which 90% of bacteria are destroyed).[1,2] Concerns about the emerging resistance to vancomycin, coupled with the lack of protective effect against endophthalmitis of antibiotics used in irrigating fluid, has led to the recommendation that vancomycin should not be used intraoperatively.[2,4]

In contrast, the **intracameral injection of the antibiotic cefuroxime (1 mg in 0.1 ml normal saline) at the conclusion of cataract surgery** has caused a reduction in the number of cases of endophthalmitis. The European Society of Cataract and Refractive Surgeons (ESCRS) multicentre study was stopped early when it was found that the absence of cefuroxime administration at the end of cataract surgery was associated with a five- to six-fold increase in the risk of endophthalmitis[8] (see page 11).

Cefuroxime may also be protective against endophthalmitis when it is given as a **subconjunctival injection** at the end of surgery. Therapeutic levels of cefuroxime in the anterior chamber are achieved after 12 to 24 minutes following subconjunctival injection and levels continue to rise beyond two hours.[4] There is some evidence for this: other subconjunctival antibiotics given at the conclusion of cataract surgery have been found to reduce the risk of endophthalmitis.[4]

Protocol for treating endophthalmitis

- Admit the patient, stop antibiotics, and prepare for theatre.
- Perform a vitreous tap with or without capsulectomy.
- Give an intravitreal injection of vancomycin 2 mg and cefuroxime (or ceftazidime) 2 mg (or 0.5 mg amikacin if the patient is allergic to penicillin).
- Give a subconjunctival injection of vancomycin 50 mg and cefuroxime (or ceftazidime) 125 mg (or amikacin 50 mg if the patient is allergic to penicillin).
- Send the vitreous sample for microscopy and culture.
- Monitor the pain experienced by the patient. A reduction in pain suggests bacterial kill.
- Start instilling vancomycin 5% and ceftazidime 5% eyedrops hourly.
- If you cannot see the posterior segment, do an ultrasound B-scan, if this is available.
- If there is no improvement within 24 hours, consider repeating the vitreous sample and the antibiotic injections.
- Consider topical or systemic steroids if you are confident the infection is under control (i.e. pain is diminishing, fibrin is contracting, hypopyon is decreasing).
- Taper the treatment according to the patient's response and culture results.
- Keep the patient informed of progress.

Note: Vancomycin and cefuroxime (or ceftazidime) must not be mixed in the same syringe – draw up in separate syringes.

Reproduced by kind permission of The Royal College of Ophthalmologists

Postoperative treatment and follow-up

There is insufficient data on the effectiveness of the postoperative use of topical antibiotics in reducing rates of endophthalmitis, although this is a widespread pratice amongst surgeons.[1] Following uncomplicated cataract surgery, the routine review of patients on the first postoperative day is not necessary, due to the low rate of sight-threatening complications.[10] However, a review on the first day is probably recommended when patients have had complicated cataract surgery, surgery on an eye with co-existing disease (such as uveitis or glaucoma), or surgery performed on an only eye and when patients do not have ready access to eye services.[10]

Summary

Multiple factors can lead to endophthalmitis. The source of the bacteria is considered to be from the patient's own ocular surface or adnexa. For this reason, simple measures in the preparation of the patient have a dramatic effect on the reduction of endophthalmitis rates, in particular the instillation of povidone-iodine and careful draping to isolate the lid and lashes. The use of antibiotics at the conclusion of surgery, especially intracameral or subconjunctival cefuroxime, is also recommended.

References

1 Mamalis N, Kearsley L, Brinton E. Postoperative endophthalmitis. Curr Opin Ophthalmol 2002;13: 14–18.
2 Buzard K, Liapis S. Prevention of endophthalmitis. J Cataract Refract Surg 2004;30: 1953–1959.
3 Eifrig CWG, Scott IU, Flynn HW Jr, Miller D. Endophthalmitis caused by Pseudomonas aeruginosa. Ophthalmology 2003;110: 1714–1717.
4 Kamalarajah S, Ling R, Silvestri G, Sharma NK, Cole MD, Cran G, Best RM. Presumed infectious endophthalmitis following cataract surgery in the UK: a case-control study of risk factors. Eye 2007;21: 580–586.
5 Schmitz S, Dick HB, Krummenauer F, Pfeiffer N. Endophthalmitis in cataract surgery: results of a German study. Ophthalmology 1999;106: 1869–1877.
6 Leyland M, Bacon A, Watson SL. Risk factors for endophthalmitis: does non-wearing of facemasks increase relative risk? Eye 2007;21: 1441.
7 Trivedi RH, Wilson ME Jr. As surgeons, our view of postcataract surgery endophthalmitis prevention is still not clear. Eye 2007;21: 577–579.
8 ESCRS Endophthalmitis Study Group. Prophylaxis of postoperative endophthalmitis following cataract surgery: results of the ESCRS multicenter study and identification of risk factors. J Cataract Refract Surg 2007;33: 978–988.
9 Olson RJ. Reducing the risk of postoperative endophthalmitis. Surv Ophthalmol 2004;49: S55-S61.
10 Alwitry A, Rotchford A, Gardner I. First day review after uncomplicated phacoemulsification: is it necessary? Eur J Ophthalmol 2006;16: 554–559.

Using intracameral cefuroxime as a prophylaxis for endophthalmitis

David Yorston
Consultant Ophthalmologist, Tennent Institute of Ophthalmology, Gartnavel Hospital, 1053 Great Western Road, Glasgow G12 0YN, Scotland, UK.

Barry P, Seal DV, Gettinby G, Lees F, Peterson M, Revie CW; ESCRS Endophthalmitis Study Group

ESCRS study of prophylaxis of postoperative endophthalmitis after cataract surgery: preliminary report of principal results from a European multicenter study

J Cataract Refract Surg 2006 Mar;32(3): 407–10

Purpose: To report results of the European Society of Cataract & Refractive Surgeons (ESCRS) multicentre study of the prophylaxis of endophthalmitis after cataract surgery.
Setting: Twenty-four ophthalmology units and eye clinics in Austria, Belgium, Germany, Italy, Poland, Portugal, Spain, Turkey, and the United Kingdom, with an administrative office in Ireland, a coordinating centre in England, and a data management and statistical unit in Scotland.
Methods: This partially masked randomised placebo-controlled multinational clinical study aimed to evaluate prospectively the prophylactic effect of an intracameral cefuroxime injection and/or perioperative levofloxacin eyedrops on the incidence of endophthalmitis after phacoemulsification cataract surgery. The study began in September 2003 and was terminated early in January 2006. The study used random allocation of patients in a 2x2 factorial design.
Results: By the end of 2005, complete follow-up records had been received for 13,698 study patients. Such a clear beneficial effect from the use of intracameral cefuroxime had been observed that it was agreed it would be unethical to continue the study and to wait for the completion of all follow-up procedures before reporting this important result. If total reported cases of endophthalmitis are considered, the incidence rate observed in those treatment groups **not** receiving cefuroxime prophylaxis (23 cases in 6,862 patients) was almost five times as high (odds ratio [OR] 4.59; 95% confidence interval [CI] 1.74–12.08; p=0.002) as that in the groups receiving this treatment (5 cases in 6,836 patients). If only cases proved to be due to infection are considered, the rate was more than five times as high (OR 5.32; 95% CI 1.55–18.26; p=0.008) in the treatment groups not receiving cefuroxime. Although the use of perioperative levofloxacin eyedrops as prophylaxis was also associated with a reduction in the observed incidence rate of postoperative endophthalmitis, this effect was smaller and was not statistically significant, whether total reported cases or only cases proven to be due to infection were used in calculating the rates. As not all follow-up procedures are complete, it is possible that further cases of endophthalmitis may be reported; however, it is not expected that this will alter the main conclusion. Nevertheless, it is anticipated that successful completion of follow-up procedures in all patients will increase the total number in the study to approximately 16,000.
Conclusion: Intracameral cefuroxime administered at the time of surgery significantly reduced the risk for developing endophthalmitis after cataract surgery.

Comment

This paper presents the results of a large and well-designed randomised trial, which examined the effectiveness of an injection of cefuroxime 1 mg in the anterior chamber at the conclusion of cataract surgery. The results showed such a great benefit from the use of cefuroxime that the trial was stopped early, because it was considered unethical not to use the treatment.

From these figures, out of 10,000 cataract operations without postoperative intracameral cefuroxime, 23.3 would be expected to develop culture-positive endophthalmitis. With intracameral cefuroxime, this number would only be 4.4 (OR=5.32, 95%; CI 1.55–18.26). Globally, 10 million cataract operations are performed every year. This gives an incidence of endophthalmitis of 23,000 per year. If all surgeons used intracameral cefuroxime in every case, the incidence of endophthalmitis would be reduced to 4,400.

What about toxicity? It appears that the intracameral injection of cefuroxime is not toxic: Swedish researchers have published results on many thousands of eyes that have received intracameral cefuroxime without any adverse effects.[1]

It is possible that these results on the prophylactic effect of intracameral cefuroxime might be different in developing countries. This study was carried out in Europe, and it was also carried out on eyes that were having phacoemulsification. It is likely that the majority of these eyes had clear corneal incisions, with no sutures. Few clinics in developing countries routinely use phacoemulsification.They tend to favour extracapsular extraction, a technique in which the wound is covered with a conjunctival flap and which may be associated with a lower risk of infection. However, since the type of wound closure is not the only factor in the occurrance of endophthalmitis, similar prophylactic results may be obtained with the intracameral injection of cefuroxime at the end of extracapsular cataract extraction.

Despite these uncertainties, this study represents the best evidence we have regarding the prevention of this devastating complication.

Reference
1 Montan PG, Wejde G, Setterquist H, Rylander M, Zetterström C. Prophylactic intracameral cefuroxime: evaluation of safety and kinetics in cataract surgery. J Cataract Refract Surg 2002;28(6): 982–987.

Preparing a cefuroxime injection

You will need the following:
- Vial of 250 mg cefuroxime
- 2x10 ml normal saline
- 2 ml syringe
- 1 ml syringe

Method
1. Dissolve the cefuroxime in 12.5 ml of normal saline (20 mg/ml)
2. Draw up 1 ml of the cefuroxime solution (20 mg) in the 2 ml syringe
3. Make up to 2 ml with 1 ml normal saline (10 mg/ml)
4. Draw up 0.1 ml of this solution (1 mg) with the 1 ml syringe and inject into the anterior chamber, using a Rycroft cannula, through an anterior chamber paracentesis.

Recognising 'high-risk' eyes before cataract surgery

Parikshit Gogate
Head, Department of Paediatric Ophthalmology, Community Eye Care, HV Desai Eye Hospital, Pune 411028, India.
Email: parikshitgogate@hotmail.com

Mark Wood
Consultant Ophthalmologist, CCBRT Hospital, Box 23310, Dar es Salaam, Tanzania.
Email: markwood@cats-net.com

Certain eyes are at a higher risk of complication during cataract surgery. Operations on such 'high-risk' eyes are also more likely to yield a poor visual outcome (defined as best corrected vision less than 6/60 after surgery).[1]

Learning to recognise when eyes are at greater risk, and acting accordingly, will help you to avoid complications. Even so, before the operation takes place, it is good practice to explain to such patients that a poor outcome is a possibility. This makes these patients' expectations more realistic and improves postoperative compliance and follow-up. In most cases, patients who are blind with complicated cataract will be happy with even a modest improvement of their vision.

It is also important to have available all the equipment you may need to manage a possible complication, for example a vitrectomy machine in the case of capsular rupture and vitreous loss.

Depending on where you are in the world, certain 'high-risk' eyes will be more common: for example, pseudoexfoliation in Somalia and India, onchocerciasis in Sudan, and angle-closure glaucoma in Asia. You will get to know your local problems as you perform more operations.

Before you operate

Get an accurate patient history. In particular, obtain information on trauma, previous operations, diabetes, dry eye, amblyopia, and congenital abnormalities. If the patient has only one eye, it is necessary to find out what caused the loss of the other eye.

Perform a thorough eye examination. This should include:

- **Measuring best corrected visual acuity.** This will determine whether a potentially risky operation should be attempted or avoided. If the patient only has one eye, is the patient content with his or her present vision? Be aware that you could make it worse.
- **A slit lamp examination with dilated pupil.** Many potential problems become visible when the pupil is dilated. A slit lamp examination will identify most problems you are liable to face during surgery, such as subluxated lenses. Check the maturity of the lens, the condition of the capsule, and whether the cataract really is the cause of the patient's poor vision, before deciding to perform a potentially risky operation.

Bruce Noble

Conjunctivitis

- **Measuring intraocular pressure.** It is important to measure intraocular pressure in all patients, for example to identify glaucoma.
- **A fundus examination.** The fundus can be seen through all but the densest cataracts. You can do a B-scan if the medium is not clear.

Your examination should be able to identify problems or signs which indicate that the operation may not be straightforward.

During the examination, you will need to pay attention to the following areas, which are discussed in this article:

- infection
- potential visualisation problems
- anatomy of the anterior segment
- crystalline lens profiles
- other health conditions.

Infection

Any infection in or around the eye could lead to **endophthalmitis**; infections should therefore be treated before surgery.

A blocked and infected lacrimal sac may cause endophthalmitis. It is extremely important to check the sac patency before surgery. If the sac has mucoid regurgitation, instil local antibiotic drops and postpone surgery. A dacryocystectomy (DCT) or dacryocystorhinostomy (DCR) may be done if antibiotics do not resolve the condition before surgery is to take place.

Entropion, ectropion, and lagophthalmos: these eyes may have corneal exposure before and after surgery. Eyelashes rubbing on the eye are a source of infection. In such eyes, the postoperative use of steroids may precipitate a corneal ulcer. In addition, lack of a proper lid closure mechanism will not allow the eye drops instilled to stay in the conjunctival sac. These three conditions need to be corrected by surgery before you can contemplate a cataract extraction.

Conjunctivitis should be treated with topical antibiotics prior to intraocular surgery.

Potential visualisation problems during surgery

Corneal opacity

Leucoma-grade opacity will make your task extremely difficult. You will find it difficult to see details, in particular the capsulotomy. There may be residual lens matter remaining in the bag, which will be difficult to see. It will also be challenging to place the intraocular lens (IOL) in the posterior chamber with both haptics under the iris.

Patients suffering from trachoma with pannus, corneal dystrophy, degeneration, and band-shaped keratopathy, have hazy corneas. Raised intraocular pressure may cause epithelial oedema. Phenylephrine dilating drops, if used too frequently, may cause epithelial haze. Even minimal corneal handling during surgery may decrease corneal clarity.

Older patients, and those with Fuchs' dystrophy, uveitis, or glaucoma, may have a compromised endothelium; their corneas may decompensate after surgery. The use of high-viscosity viscoelastics, such as Healon GV (sodium hyaluronate), and minimal anterior chamber manipulations may help preserve the endothelium.[2,3] It may be advisable to perform extracapsular cataract extraction (ECCE), rather than phacoemulsification or manual small incision cataract surgery (SICS).[4]

If there is a central corneal scar obscuring the pupil, an optical sector iridectomy may be helpful.

A small pupil

A small, rigid pupil poses a problem in both ECCE and SICS. Any unnecessary manipulation of the iris can result in a small pupil. This will make it difficult to see residual lens matter, the position of the IOL, and the

Margreet Hogeweg

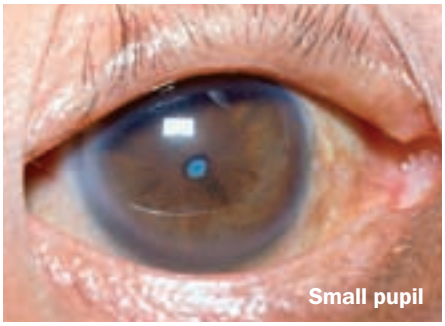

Small pupil

anterior capsule for capsulotomy.

A small pupil can be dealt with in the following ways:

- Intracameral phenylephrine can be tried first.
- A Sinskey hook or Y-shaped IOL dialler can be used to stretch the pupillary sphincter. The instruments are placed 180° apart and the pupil stretched right out to the limbus for ten seconds.
- If the pupil is still too small, a sphincterectomy (three small radial cuts on the sphincter pupillae, 120° apart) can be done to facilitate nucleus delivery (Figure 1).
- Finally, iris hooks may be used to dilate the pupil.

If the surgeon is fastidious about having a round pupil postoperatively, a small peripheral iridectomy can be made and the cut extended to the pupillary margin (radial iridotomy). The iridotomy can be sutured later using 10-0 Prolene interrupted sutures (Figure 2); this procedure demands considerable skill and patience. However, this is not often required.

Figure 1: Sphincterotomy for a small, rigid pupil: three cuts made 120° apart

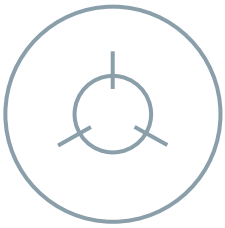

Figure 2: Radial iridotomy sutured with 10.0 interrupted sutures

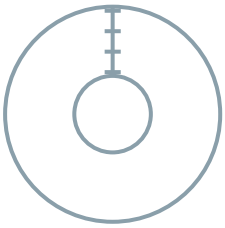

Anatomy of the anterior segment

Narrow anterior chambers

These eyes make it difficult to perform intraocular manipulations and to move the instruments in and out of the eye. This increases chances of iris injury and iridodialysis at the iris root (the thinnest part of the iris) and at its major arterial circle. A narrow chamber occurs in hypermetropic eyes, while deep anterior chambers occur in high myopes.

High ametropia

High hypermetropia or myopia create specific problems.

The surgeon must re-check the A-scan and keratometer findings of IOL power, as errors are common in high myopia and high hypermetropia. It is worth trying to do a refraction to help assess the A-scan readings. Very dense and mature cataracts can give erroneous readings. When in doubt, it is better to veer on the side of slight myopia postoperatively. Most patients prefer to see clearly in the medium-to-near distance without spectacle correction.

Highly myopic patients have a wide angle, which facilitates instrument entry. However, the nucleus can be very large and the chamber deep. A deep anterior chamber may be caused by a 'reverse pupil block'. In this situation, the iris should be raised from the capsule to even out the pressure; the chamber depth will then return to normal.[5]

Viscoelastics help to maintain anterior chamber depth where necessary and to ease the insertion of instruments. The entry and exit of instruments should be kept to a minimum.

Crystalline lens profiles

The cataracts mentioned below will test a surgeon's skill, experience, and patience. In ECCE, a capsular tension ring (CTR) can be inserted after doing a continuous (complete) circular capsulo rhexis (CCC) to stabilise the bag.[6] Note that it is more important that the CCC be 'complete' than it be 'circular', because an intact capsular margin ensures that the zonular tension is equally divided all around. Keep hydrodissection to a minimum. If you are using phacoemulsification, do it 'in the bag'. If you are using ECCE or SICS, gently rotate the nucleus into the anterior chamber (do not tumble) and then deliver it outside the incision. All are difficult procedures. It may be easier to remove the lens (possible intracapsular extraction with vectis loop or lensectomy) and implant an anterior chamber lens.

- **Hard, dense nuclei** are difficult to remove with phacoemulsification or SICS. You may prefer to do a routine extracapsular extraction.[4]
- **Hypermature cataracts** have a small nucleus and a wrinkled capsule. Anterior capsulotomy may be difficult.
- **Milky cataract (Morganian):** when making the capsulotomy, the 'milk' from the cataract fills the anterior chamber, obscuring the surgeon's view. The anterior capsulotomy may not be complete. Filling the anterior chamber with viscoelastic before starting the capsulotomy may help.
- **Fibrotic anterior capsule:** these very thick, tough capsules may have to be cut with scissors.
- **Pseudoexfoliation** causes weak zonules and glaucoma. There is an increased chance of zonular dialysis.
- A **subluxated or dislocated lens** can occur in many conditions: very mature lenses, pseudoexfoliation, trauma, Marfan's syndrome, and other syndromes.

Bruce Noble

Dislocated lens after trauma

Traumatic cataracts can give nasty surprises. The following steps may help you deal with them:

- Do an ultrasound B-scan before surgery.
- There may be corneal or iris tears that need to be repaired. Make a small incision at the 12 o'clock position and use air or viscoelastic to form the anterior chamber before suturing the cornea.
- The anterior capsule may be broken or torn. The tear can be extended as a CCC or an 'envelope' capsulotomy.
- Keep the hydrodissection minimal, as there may be a posterior capsular tear.
- If there is a posterior capsular tear, perform dry aspiration under cover of viscoelastic.
- Anterior vitrectomy is necessary if the posterior capsule is torn. Try and preserve as much of the capsule as possible. We normally do not put an IOL in at this stage, but rather do this as a secondary procedure.

Membranous cataract occurs when the lens matter has been absorbed and the anterior and posterior capsules fuse. A capsulotomy, possibly followed by an anterior vitrectomy, should clear the opacity. Leave enough capsule to support an IOL. This IOL will have to be placed in the sulcus.

Aaron Sobol (http://drsobol.com)

Uveitis

Uveitis causes synechiae and cataract. Posterior synechiae can be gently separated using an iris repositor after instilling viscoelastic. This will probably mean that you will perform a 'can-opener' capsulotomy. The sphincter pupillae may still need to be stretched. Keep iris handling to a minimum in cases of uveitis, at it may trigger postoperative inflammation. It is advisable to start oral and local steroids a few days before surgery.

Other health conditions

Glaucoma:

- Eyes with long-standing glaucoma have poor endothelial cell counts; postoperative corneal oedema may occur.
- Eyes that have been treated for many years with anti-glaucoma agents, like pilocarpine, may have pupils resistant to dilation.
- Complications like iris injury, capsular tear and zonular dialysis can all aggravate pre-existing glaucoma.
- Previous trabeculectomy means that the functioning bleb must be preserved during cataract surgery, by using either a corneal incision (phacoemulsification) or a

Continues overleaf ➤

temporal approach. To complicate matters, synechiae and a shallow anterior chamber are often present.

HIV-positive patients: cataract surgery in these patients requires routine (and thus proper) care. However, such patients may have posterior segment complications such as cytomegalovirus (CMV) retinitis, vasculitis, and choroiditis, which may not be evident in a white cataract. Performing a B-scan may not always be helpful, but it should be done when fundus details are not clear. These patients are also prone to secondary infection.

Diabetes: it is important to try and keep the posterior capsule intact. Retinopathy progresses more rapidly in diabetic patients after cataract surgery and a ruptured capsule can be a factor in rubeosis. Close follow-up and timely laser treatment are required. If possible, treat the retinopathy preoperatively with laser.

Onchocerciasis: this disease affects the cornea, uvea, and retina. In endemic areas, cataract surgery can be disappointing due to optic nerve and retinal pathology. You must take care when selecting patients for cataract surgery, in order to avoid performing operations which will bring no benefit to patients.

Hypertension and high positive pressure during surgery: in general, it is important to avoid a high positive pressure during surgery. This can be caused by an inadequate or excessive peribulbar block, or a tight bridle suture. It is therefore important to control hypertension in patients. In addition, retrobulbar haemorrhage should be identified early and the operation postponed. Expulsive haemorrhage in one eye could alert you to possible problems in the second eye.

Asthma, chronic obstructive pulmonary disease and constipation: when in doubt about whether to suture the wound, it is always better to do so – especially in patients suffering from these conditions.

References

1 Limburg H. Monitoring cataract surgical outcomes: methods and tools. Community Eye Health J 2002; 15(44): 51–3.
2 Gogate PM, Kulkarni SR, Krishnaiah S, Deshpande RD, Joshi SA, Palimkar A et al. Safety and efficacy of phacoemulsification compared with manual small incision cataract surgery by a randomised controlled clinical trial: six weeks results. Ophthalmology 2005;112: 869–874.
3 Basti S, Vasavada AR, Thomas R, Padmanabhan P. Extracapsular cataract extraction: Surgical techniques. Indian Journal of Ophthalmology 1993;41: 195–210.
4 Bourne RR, Minassian DC, Dart JK et al. Effect of cataract surgery on the corneal endothelium: modern phaco-emulsification compared with extra capsular cataract surgery. Ophthalmology 2004;111(4): 679–85.
5 Cionni RJ, Barros MG, Osher RH. Management of lens-iris diaphragm retropulsion syndrome during phacoemulsification. J Cataract & Refract Surg 2004; 30: 953–956.
6 Ahmed IK, Cionni RJ, Kranemann C, Crandall AS. Optimal timing of capsular tension ring implantation: Miyake-Apple video analysis. J Cataract & Refract Surg 2005;31: 1809–1813.

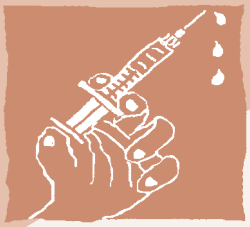

HOW TO

Administering an eye ana

Ahmed Fahmi
Paediatric Ophthalmology Fellow, CCBRT Disability Hospital, Tanzania.
Email: biophku@yahoo.com

Richard Bowman
Ophthalmologist, CCBRT Disability Hospital, Tanzania; Honorary Senior Lecturer, London School of Hygiene and Tropical Medicine.
Email: richardbowman@raha.com

Rationale

The trigeminal nerve carries the sensory innervation of the eye and adnexa in three divisions: ophthalmic, maxillary, and mandibular. The sensory fibres of the eye and adnexa are found in the ophthalmic division – with the exception of a portion of the sensory input from the lower lid, which is carried by the maxillary division. Blocking the sensory fibres provides **anaesthesia** so that no pain is felt.

The motor supply of the extraocular muscles and levator palpebrae superioris is carried by the oculomotor (III), trochlear (IV), and abducens (VI) nerves. Paralysing these muscles by blocking their motor supply provides **akinesia** so that the eye does not move during surgery.

The motor supply of the orbicularis oculi, which is responsible for the gentle and forcible closure of the eye, is carried by the facial nerve (VII). Blocking these fibres will provide better surgical exposure. It also reduces the risk of forcing out the ocular contents if the patient tries to close his eyelids forcibly after the surgeon opens the globe.

Anatomy

It is important to recall the anatomy and to have a precise knowledge of the various injection sites for the anaesthetic. The anteroposterior diameter of the globe averages 24.15 mm (range: 21.7 to 28.75 mm). The axial length of myopic eyes are at the upper end of this range. This increases the risk of globe perforation, especially with a retrobulbar block. The length of the bony orbit is about 40 to 45 mm. On average, the anatomic equator is about 13 to 14 mm behind the limbus along the surface of the globe. At its closest distance to the bony orbit, the globe is about 4 mm from the roof, 4.5 mm from the lateral wall, 6.5 mm from the medial wall, and 6.8 mm from the floor.

The **retrobulbar space** lies inside the extraocular muscle cone, behind the globe. Relatively avascular areas of the orbit are confined to the anterior orbit in the lower outer (inferotemporal) and upper outer (superotemporal) quadrants. **The superonasal quadrant** is highly vascular and has limited space.

Tenon's capsule is the anterior extension of the visceral layer of dura investing the optic nerve. Therefore, the **sub-Tenon's space** is continuous with the subdural space and is, in effect, an anatomical pathway from the limbus to the retrobulbar space. Because the conjunctiva fuses with Tenon's capsule 2 to 3 mm behind the limbus, the sub-Tenon's space can be accessed easily through a scissor snip made there.

Choosing the anaesthesia technique

Decide in advance what technique you are going to use. A **retrobulbar block** is more efficient in producing anaesthesia and akinesia and has a faster onset of action. However, it carries a higher risk of rare, yet serious, complications, such as globe perforation, retrobulbar haemorrhage, and injection of the anaesthetic into the cerebrospinal fluid (CSF). Mastering the technique reduces these risks significantly.

The probability of complications is reduced in a **peribulbar block**; however, this technique is slower and less efficient, it carries a higher risk of potential chemosis, and it puts more pressure on the eye. A retrobulbar block should be avoided if the axial length of the eye is greater than 27 mm.

When a retrobulbar or peribulbar block is unsatisfactory, you can add a **sub-Tenon's block**; it is a suitable supplement. By itself, the sub-Tenon's block is useful for shorter procedures, provided you are operating on cooperative patients. The sub-Tenon's block is more likely to be performed by an ophthalmic surgeon than by an ophthalmic anaesthetist. It enables top-up injections to be easily and safely given. Sub-Tenon's blocks are less likely to cause systemic complications than retrobulbar or peribulbar blocks.[1]

esthetic: principles, techniques, and complications

The anaesthetic solution

Components

Lignocaine 2% is the most popular agent for nerve blocks. It has a rapid onset of action and its effect will usually last for an hour. **Bupivacaine 0.5%** lasts for three hours or even longer; this anaesthetic can be useful for prolonged procedures such as vitreoretinal surgery.

Hyaluronidase may increase the effectiveness of a block by facilitating the spread of lignocaine or bupivacaine through the tissues. Hyaluronidase can be used in a concentration of approximately 50 units/ml (range: 25 to 75 ml).

Adrenaline slows the absorption of anaesthetic agents into the systemic circulation. This will provide a longer duration of action and reduce the risk of systemic toxic effects. It is used in a concentration of 1:100,000.

Preparing the solution

- To use hyaluronidase, add one ampoule (containing 1,500 units) to a 20 ml or 50 ml bottle of lignocaine 2% or bupivacaine 0.5% (this only stays active for few days after mixing).
- To use adrenaline, add 0.1 ml from a vial of 1:1,000 adrenaline to 10 ml of the anaesthetic solution (to get 1:100,000).

Note: Lignocaine often comes already premixed with 1:100,000 adrenaline.

Basic steps: all techniques

- Introduce yourself to the patient. Explain the procedure in a short, simple, and understandable way and reassure the patient.
- Check the patient's full name, the eye assigned for surgery, and the type of surgery required.
- Record blood pressure, pulse rate, and respiratory rate as a baseline for the monitoring of vital signs. These observations should be repeated every two to three minutes after the injection. Where available, pulse oximetry should be used during injection and surgery.
- Check that resuscitation equipment and medication is available to deal with a systemic complication, should one occur.
- Lie the patient flat in a safe and comfortable way, with head supported.
- Ask the patient to look straight ahead (not upwards or nasally); hold the patient's hand in front of his or her eye and ask him or her to look at it.
- Withdraw the plunger of the needle slightly before injecting the anaesthetic to make sure that you have not entered a blood vessel (blood) or the dural sheaths (CSF).
- Assess the efficiency of the anaesthesia by asking the patient to look in the four cardinal positions of gaze.
- Recall the possible complications (see box below), look out for their clinical manifestations, and be prepared to manage them. Anticipate complications in eyes with high axial length and in uncooperative patients. Staff should attend resuscitation courses annually to familiarise themselves with the handling of serious complications.

Richard Bowman and Ahmed Fahmi

Figure 1. Retrobulbar injection: the needle is passed through the junction of the middle and outer third of the inferior orbital rim, then straight back below the eye for 15 mm. The needle should be parallel to the floor of the orbit and angled down.

Retrobulbar block

- Prepare the injection: 2 to 3.5 ml of the anaesthetic solution in a syringe with a sharp 23-gauge 24 mm needle (not 38 mm). The needle should not have an acute bevel.
- Feel the lower orbital rim and pass the needle through the skin or the conjunctiva at the junction of its lateral (outer) and middle thirds. The bevel of the needle should be pointing upwards. The needle should be passed straight back below the eye for 15 mm; it should be parallel to the floor of the orbit and angled down (Figure 1). You might feel the resistance as you pass through the orbital septum.
- Change the direction of the needle so that the tip is pointing upwards and inwards

Continues overleaf ➤

Complications of retro- or peribulbar anaesthesia

Retrobulbar haemorrhage is indicated by a hard and tense orbit with no retropulsion of the globe, proptosis, and subconjunctival haemorrhage. Management is usually conservative: surgery needs to be postponed. However, if the eye is very hard, you should perform an emergency lateral canthotomy to relieve pressure on the globe: clamp the lateral canthus with an artery forceps for 30 seconds, then cut it with sharp scissors.

Globe perforation is a rare and serious complication. Its adverse effects can be reduced if the anaesthetic is not injected because the complication has been recognised in time. You should suspect a globe perforation if the eye becomes soft as you insert the needle. If the globe has been engaged by the needle, it will not move as you ask the patient to move his eye from side to side. Be very careful with your technique: advance the needle gently and take particular care in eyes with a high axial length (the needle should be kept further away from the globe).

Systemic complications are very rare but very serious when they occur – they might be fatal. These complications occur if the local anaesthetic was injected into a blood vessel or into the cerebrospinal fluid. The latter complication can be avoided by not advancing the needle more than 24 mm from the entry site and by asking the patient to look straight ahead (as proved by CT scan studies). Systemic complications manifest as circulatory collapse, disturbance in the level of consciousness (drowsiness), pulse irregularities, or convulsions.

Richard Bowman and Ahmed Fahmi

Figure 2. Retrobulbar injection: the needle is advanced and the antibiotic injected after the needle's direction was changed so that the tip points upwards and inwards towards the opposite occipital eminence (slightly to the opposite side of the midline of the back of the skull). Note the drooping of the upper lid.

Richard Bowman and Ahmed Fahmi

Figure 3. Peribulbar block: the needle is inserted through the fornix below the lateral limbus after the lower fornix was exposed (by pulling the lower lid down gently).

Richard Bowman and Ahmed Fahmi

Figure 4. Peribulbar block: the needle is advanced between the caruncle and the medial canthus in a backwards and medial direction, away from the globe.

Richard Bowman and Ahmed Fahmi

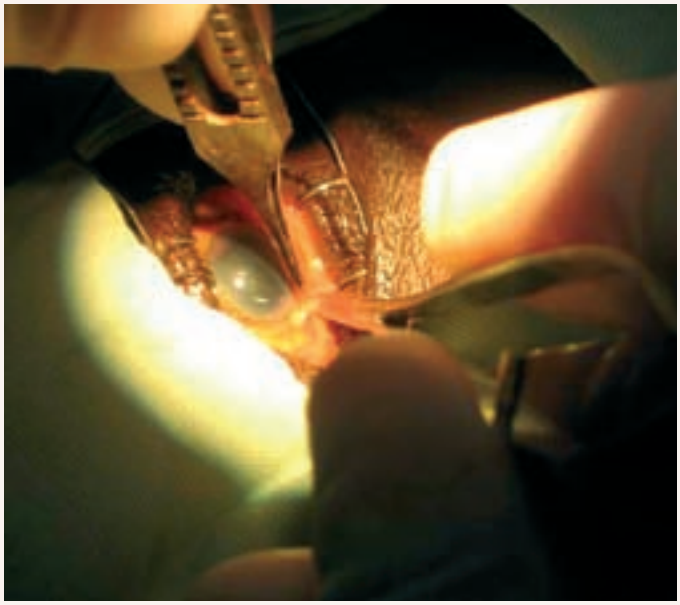

Figure 5. Sub-Tenon's block: a pair of spring scissors is held perpendicularly to make a small (0.5 mm) snip incision through both the conjunctiva and Tenon's capsule, 2 to 3 mm behind the limbus in the inferomedial quadrant.

towards the back of the skull. Feel the resistance as the needle passes through the muscle cone. The needle should be advanced not more than 24 mm from the skin in total (Figure 2).

- Inject slowly and look for dilation of the pupil and drooping of the upper lid.
- Close the eyelids gently, cover with a pad, and immediately apply firm, gentle pressure for 5 to 10 minutes. This can be done manually or with a special balloon inflated to 30 mmHg.

Note: A failed block can be repeated only once.

Peribulbar (periconal) block

This block consists of two injections; it is injected inferotemporally and between the caruncle and medial canthus.

- Prepare the syringe: 7 to 10 ml of the anaesthetic solution in the same syringe as for a retrobulbar block.
- Expose the lower fornix by pulling the lower lid down gently (Figure 3).
- Instil one drop of topical anaesthetic eye drops.
- Insert the needle through the fornix below the lateral limbus. Pass it backwards and laterally for not more than 24 mm. Always keep it away from the globe by directing it slightly downwards (Figure 3).
- Inject at the level of the equator
- The inferotemporal anaesthetic injection (4 to 5 ml in total) may be divided into three shots: 1 ml immediately posterior to the orbicularis oculi, 1 ml just anterior to the equator, and 2 ml after the needle is advanced past the globe.
- The second injection (3 to 4 ml in total) can be given between the caruncle and the medial canthus, then passed back and slightly medially (away from the globe) for about 24 mm, to inject 3 to 4 ml of the anaesthetic (Figure 4). Injecting directly through the caruncle can cause significant bleeding.
- The superonasal approach is now regarded as unduly dangerous and it should be abandoned. This is due to high vascularity and limited space.

Sub-Tenon's block

- Prepare 2 to 3.5 ml of anaesthetic solution.
- Instil one drop of anaesthetic eye drops. A small swab soaked in topical amethocaine and left in the lower fornix for a minute is particularly effective.
- Cauterising the space before incision is extremely helpful in limiting both the risk of subconjunctival haemorrhage and that of an unintended extension of the incision. To do this, gently apply the bipolar cautery, barely touching but not pressing down on the conjunctival surface. This also helps to lift the Tenon's capsule away from the sclera.
- Use a pair of spring scissors to make a small (0.5 mm long) snip through both the conjunctiva and Tenon's capsule, 2 to 3 mm behind the limbus in the inferomedial quadrant of the globe. The scissors should not be opened more than halfway. It is essential to find the sub-Tenon's plane, i.e. to dissect down to bare sclera. It helps to hold the scissor blades so that their plane is perpendicular to the ocular surface instead of being parallel to it (Figure 5).
- Use a specially designed blunt cannula to inject the anaesthetic. However, if you do not have a specially designed cannula, a lacrimal cannula is a suitable alternative. Mount the cannula on a syringe containing the anaesthetic solution.
- Pass the cannula through the snip incision. The incision should fit tightly around the cannula.
- Advance the cannula backwards with its tip touching and following the curvature of the globe all the way to the retrobulbar space. As the equator is passed, the hand and syringe need to rotate away from the globe so that the cannula tip stays in the space (Figure 6).
- Inject the anaesthetic carefully.

Reference

1 Eke T, Thompson JR. Serious complications of local anaesthesia for cataract surgery: a 1-year national survey in the United Kingdom. Br J Ophthalmol 2007; 91(4): 470–5.

Figure 6. Sub-Tenon's block: the hand and syringe is rotated away from the globe as the equator is passed so that the cannula tip stays in the space.

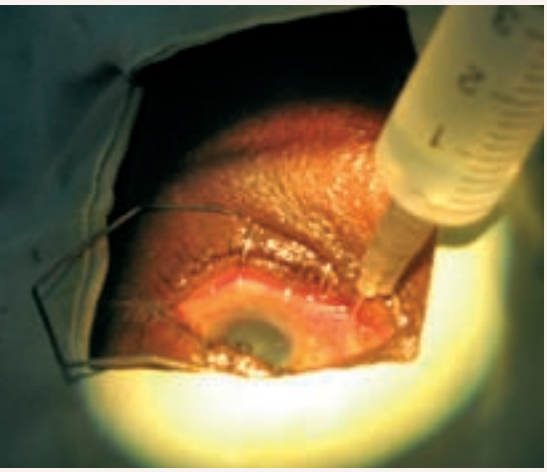

Richard Bowman and Ahmed Fahmi

HOW TO

Reducing the risk of infection: hand washing technique

Sue Stevens
Nurse Advisor to the *Community Eye Health Journal*, International Centre for Eye Health, London School of Hygiene and Tropical Medicine, Keppel Street, London WC1E 7HT, UK.

Nuwan Niyadurupola

Hand washing is a fundamental principle of infection control

Eyes are susceptible to infection by many organisms, including gram-negative bacilli, adenoviruses, the herpes simplex virus, and fungi. Infection puts eyes at higher risk of complications after cataract surgery.

Hand washing is the most important, fundamental principle of infection control. It must be strongly encouraged and practised by all disciplines in the health care setting.

Hand washing is required in the following situations:

- before any aseptic procedure
- before and after handling any patient
- after handling any soiled item
- before and after handling food
- whenever hands are, or even feel, soiled
- when entering and leaving a clinical area
- after using the toilet or assisting a patient in the toilet

Many health care workers are unaware of the need for frequent hand washing and that a certain technique is required for hand washing to be effective.

Written instructions for hand washing, as given below, should be displayed in all clinical areas.

- Wet hands with clean, preferably running, water
- Apply soap or cleanser
- Rub palm to palm
- Rub back of left hand over right palm
- Rub back of right hand over left palm
- Rub palm to palm with fingers interlaced
- Rub backs of fingers on opposing palms with fingers interlocked
- Rub around right thumb with left palm
- Rub around left thumb with right palm
- Rub palm of left hand with fingers of right hand
- Rub palm of right hand with fingers of left hand
- Rinse off soap with clean, preferably running, water, and dry well.

Rub palm to palm

Rub back of left hand over right palm and vice versa

Rub palm to palm with fingers interlaced

Rub backs of fingers on opposing palms with fingers interlocked

Rub around right thumb with left palm and vice versa

Rub palm of left hand with fingers of right hand and vice versa

REPORT

Meeting the needs of children with congenital and developmental cataract in Africa

Paul Courtright and Childhood Cataract Experts Meeting Group
Kilimanjaro Centre for Community Ophthalmology PO Box 2254, Moshi, Tanzania

In much of Africa, childhood cataract is becoming one of the leading causes of new cases of blindness reported per year.[1]

Although there is insufficient data on childhood cataract, both congenital and developmental, the backlog of children in need of surgery is estimated to be around 100 children per million population. The number of new cases of corneal blindness is estimated to be around 20 children per million population per year.[2,3]

The World Health Organization (WHO) recommends that there be one paediatric ophthalmology tertiary centre per 10 million population[4]; however, few countries in Africa have reached this target. Even in settings with tertiary centres, few children are brought in for surgery; of those who are, most are brought in too late for surgeons to be able to achieve outcomes of the highest quality.[5] This can be explained by the fact that both communities and health care providers are not sufficiently aware that children can develop cataract. The lack of programmes to identify and refer children with cataract compounds this problem. It also needs to be noted that, in most hospitals or other surgical facilities, boys outnumber girls; this is primarily due to cultural constraints and does not reflect any recognised biological risk factors associated with males.[5,6]

Virtually all children receiving surgery for congenital cataract in Africa will require long term follow-up for refractive error correction and low vision care. However, follow-up remains either patchy or non-existent.[7]

Although they are still few in number, tertiary facilities for paediatric ophthalmology in Africa have strengthened the quality of their surgical services over the past three to five years. Unfortunately, better surgical services have not usually been matched by improvement in the other services needed to strengthen overall management of congenital and developmental cataract. These include better programmes promoting early identification and referral, adequate follow-up, provision of spectacles, low vision care, or referral to inclusive education.

In May 2007, the Kilimanjaro Centre for Community Ophthalmology (KCCO), with financial support from Dark & Light Blind Care, brought together 18 people from throughout Africa, as well as key personnel from Europe and Asia, to draft recommendations and to prepare a practical manual of best practice for the management of childhood cataract in Africa. This manual will be available by August 2008. Materials from the workshop are available on the KCCO website: **www.kcco.net**

Recommendations

Efforts needed at the national level in Africa to address childhood cataract

Throughout Africa, national prevention of blindness or VISION 2020 committees need to identify existing tertiary centres for paediatric ophthalmology. In collaboration with these centres, they need to define each centre's respective catchment area (population: 10 million). For each catchment area, existing data on childhood cataract should be compiled (including age, sex, and place of residence). For planning and monitoring purposes, a childhood cataract surgical rate should be calculated for each VISION 2020 district (population: one to two million). The childhood cataract surgical rate states how many cataract operations should be performed in each district per year in order to eliminate the condition among the children residing in the district.

This information should be used to identify districts where the actual number of cataract operations performed is too low and to monitor annual progress towards reducing childhood blindness due to cataract.

Identifying and referring children with cataract

Evidence suggests that the use of key informants (at the community level) may increase identification and referral of children requiring surgery, particularly when local cultures are relatively cohesive and when people living in the geographic area know each other.[8,9] Additional research is needed to test this method for sustainability and to test it in other settings. It should also be compared with other approaches, such as the use of health workers (for example, those doing immunisations).

In many countries, children with cataract are still admitted to schools for the blind. National policies on admission of children to schools for the blind (in particular, ophthalmological examination prior to admission) are either absent or not enforced. All those engaged in eye care, education, and rehabilitation of children need to collaborate to first provide children with the best possible eye care before placing them in appropriate educational settings.

The exact timing of cataract surgery depends upon the individual characteristics of each child. However, when a child's pupil is white, health care staff must treat this as an emergency and ensure that the child is seen by an ophthalmologist as soon as possible. To ensure this, the curricula for training mid-level and primary level health providers should be reviewed and upgraded, if necessary. It would also be helpful to improve the knowledge and skills of existing care providers.

Financing cataract surgery in children

For a paediatric ophthalmology tertiary centre, the cost of equipment, consumables (e.g. high-power intraocular lenses and spectacle frames for babies and small children), and recurrent expenses are very high and require adequate funding. In most cases where programmes have achieved a significant increase in the number of opera-

K Hennig

A child prepared for cataract surgery. NEPAL

A girl with bilateral cataract. TANZANIA

Elizabeth Kishiki

tions in children, it has been necessary to waive surgical fees and to reimburse much of the travel expenses incurred by families bringing children for surgery and follow-up. These approaches may need to be considered in most settings in Africa and will require dedicated financial support.

Surgical intervention and surgical facilities

All children (in particular, younger children) should only be operated on by paediatric ophthalmologists in well-equipped tertiary centres; these centres need to ensure that high-quality paediatric anaesthetic services are available. A paediatric ophthalmology tertiary centre should have a 'childhood blindness coordinator' on the staff. This person will be responsible for counselling parents (and older children), organising activities for early detection, training health staff, and implementing a tracking system to ensure that children are brought back for follow-up, spectacles, and low vision care. Every tertiary centre should have facilities to provide low vision services and spectacles for children.

Follow-up after surgery is essential throughout childhood. All centres providing surgery should adopt strategies that have been shown to be effective in promoting regular follow-up; these strategies include counselling, keeping good records, using cell phones (mobile phones) to keep in touch, reimbursing transport costs, and organising family visits by local eye care workers.

Decentralisation of follow-up services

Low vision services and some refractive services should be decentralised as much as possible, in particular because refractive error changes periodically in children. Relevant personnel in districts served by the tertiary centre should be trained to provide basic follow-up services. It will be challenging to link tertiary and district services to ensure that children are kept track of. To ensure good practice, it is essential to establish systems of accountability.

Linking eye care, low vision, education, and rehabilitation services

Successful low vision service provision requires strong links between eye care and low vision services, as well as accurate refraction and near vision assessment. In addition, low vision services should have links with education and rehabilitation services. In most settings, special education teachers and rehabilitation workers need additional training. Eye care providers need to take the lead in initiating and maintaining low vision and educational support of children.

References

1 Waddell KM. Childhood blindness and low vision in Uganda. Eye 1998;12: 184–92
2 Foster A, Gilbert C, Rahi J. Epidemiology of cataract in childhood: a global perspective. J Cataract Refract Surg 1997;23: 601–4.
3 Gilbert C, Raji JS, Quinn GE. Visual impairment and blindness in children. In: Johnson GJ, Minassian DC, Weale RA et al, eds. Epidemiology of eye disease. London: Arnold Publishers, 2003.
4 WHO. Preventing blindness in children: Report of a WHO/IAPB Scientific Meeting. WHO/PBL/00.77 2000.
5 Mwende J, Bronsard A, Mosha M, Bowman R, Geneau R, Courtright P. Delay in presentation to hospital for surgery for congenital and developmental cataract in Tanzania. Br J Ophthalmol 2005;89: 1478–82.
6 Yorston D, Wood M, Foster A. Results of cataract surgery in young children in east Africa. Br J Ophthalmmol 2001;85: 267–71.
7 Muhit MA. Childhood cataract: Home to hospital. Comm Eye Health J 2004;17: 19–22.
8 Muhit MA, Shah SP, Gilbert CE, Hartley SD, Foster A. The key informant method: a novel means of ascertaining blind children in Bangladesh. Br J Ophthalmol 2007;91: 995–9.

Useful resources for cataract complications

Community Eye Health Journal back issues

Sandford-Smith J. Sutureless cataract surgery: principles and steps. Comm Eye Health J 2003;16(48): 51–53.

Schroeder B. Sutureless cataract extraction: complications, management and learning curves. Comm Eye Health J 2003;16(48): 58–59.

Books

Noble BA and Simmons IG. Complications of cataract surgery: a manual. 2nd ed. Butterworth Heinemann, 2001. Available from Waterstones. UK £54.99 plus post and packing.

Sandford-Smith J. Eye surgery in hot climates. 2nd ed. UK £9 (plus postage and packing). Available from the International Centre for Eye Health.

Other resources

Hennig A and Schroeder B. Sutureless cataract surgery: 'fishhook technique' instruction course. CD-ROM. Available free of charge from CBM.

Sandford-Smith J. Extracapsular cataract extraction with IOL implantation for developing countries. Video. UK £5 (incl. post and packing). Available from the International Centre for Eye Health.

Stevens S. Control of infection in ophthalmic practice. Poster.
Cox I and Stevens S. Sterilisation and disinfection. Poster.
Both available from the International Centre of Eye Health. Free of charge to low- and middle-income countries, UK £3 otherwise.

Suppliers' addresses

CBM: Email **procurement@cbm.org** or write to CBM Procurement, Christian Blind Mission e.V., Nibelungenstrasse 124, 64625 Bensheim, Germany.

Waterstones: 71–74 North Street, Brighton, East Sussex BN1 1ZA, UK. Email: **manager@brighton.waterstones.co.uk**

International Centre for Eye Health: Write to Jenni Sandford, London School of Hygiene and Tropical Medicine, Keppel Street, London WC1E 7HT, UK. Email: **jenni.sandford@Lshtm.ac.uk**

NEWS AND NOTICES

Meetings

World Ophthalmology Congress, 28 June–2 July, 2008, Hong Kong. For more information, visit www.woc2008hongkong.org or write to Angela Cho, Department of Ophthalmology & Visual Sciences, The Chinese University of Hong Kong, 3/F, Hong Kong Eye Hospital, 147K Argyle Street, Kowloon, Hong Kong.

IAPB General Assembly, 25–28 August, 2008. **Venue:** Hotel Panamericano, Buenos Aires, Argentina. **Theme:** Excellence and Equity in Eye Care. Registrations and hotel reservations are in progress. For more information and to book, please visit **http://8ga.iapb.org** or email **agency@lvpei.org**

Training

Planning for VISION 2020, London, UK. **Date:** July 2008. **Objectives:** to familiarise participants with the goals and objectives of VISION 2020: The Right to Sight and the principles involved in establishing community eye health programmes at regional or national level. **Target audience:** Ophthalmologists and eye health charity programme managers. **Fee:** UK £700. **More information:** Visit **www.Lshtm.ac.uk/prospectus/short/spv.html**. For applications, email **registry@Lshtm.ac.uk** or write to Registry, 50 Bedford Square, London WC1E 7HT, UK.

Professional diploma in vision rehabilitation, German Jordanian University, Jordan. **Date:** October 2008 to April 2009. **Aim:** Prepare professionals to plan and assess interventions for children with visual disability in all areas of development, using a transdisciplinary approach. **Language:** English **Target audience:** optometrists, rehabilitation workers, special educators and other professionals with relevant experience. **Fee:** US $1,400. Scholarships are available. **More information:** Visit **www.gju.edu.jo/ProfProg/VisionRehabilitation/index.html** or write to Nathalie Bussieres, German Jordanian University, PO Box 35247 Amman, 11180 Jordan.

Subscriptions

Change of address: it is important to us that you continue to receive your copy of the journal even if you move to another address or another country. If you have recently moved, or if you are planning to move, please send your name and postal address to Anita Shah, International Centre for Eye Health, London School of Hygiene and Tropical Medicine, Keppel Street, London, WC1E 7HT, UK. **Email:** **anitashah@Lshtm.ac.uk**

Community Eye Health JOURNAL

Supported by:

sightsavers INTERNATIONAL
Sightsavers International

The late Dr Hans Hirsch

cbm
Christian Blind Mission (CBM)

ORBIS
saving sight worldwide

cnhf

DARK & LIGHT BLIND CARE

Next issue

Daisy Wilson

The next issue of the *Community Eye Health Journal* will be on the theme **Eye care for older persons**