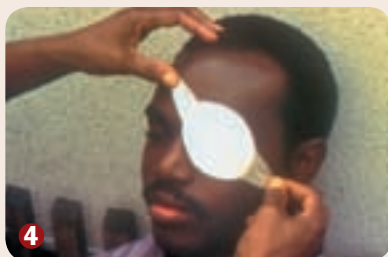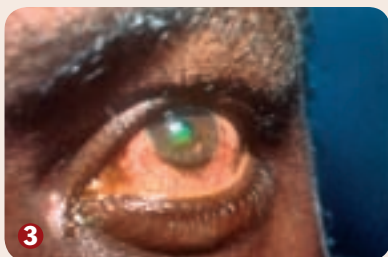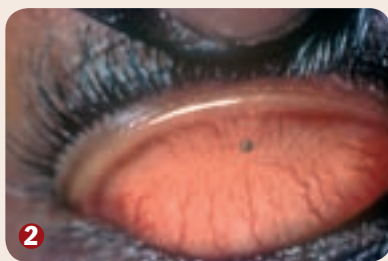


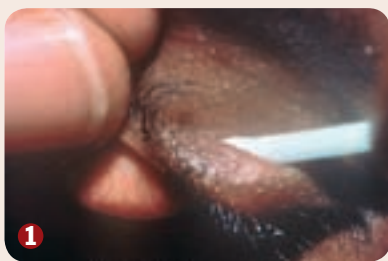Murray McGavin



Murray McGavin

## How to evert the upper eyelid and remove a sub-tarsal foreign body

### Indications

- To examine the upper tarsal conjunctiva
- To remove a foreign body (FB) and so relieve pain
- To prevent a corneal abrasion and limit further damage.

**Never evert the upper eye lid if a penetrating injury or corneal thinning (e.g., due to ulceration) is suspected.**

### You will need

- Cotton buds, paper clip or small blunt object, e.g., pen top
- Magnification
- Sterile needle
- Local anaesthetic drops
- Fluorescein strips
- Saline or cooled boiled water
- Prescribed antibiotic eye drops or ointment
- Tape, two eye pads and bandage.

### Preparation

- Explain the procedure, advising the patient that he/she may experience a brief increase in discomfort but that it is important to relax and keep still
- Reassure and encourage him/her by stressing that relief should be felt immediately after the FB is removed.

### Method

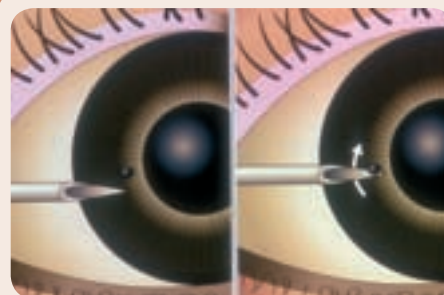
- Instil a drop of local anaesthetic and fluorescein dye
- Ask the patient to **look down**
- With one hand, hold the eyelashes of the upper eyelid between thumb and index finger
- With the other hand, place a cotton bud (or paper clip or other small blunt object) midway from the eyelid margin
- Turn the eyelid against steady and gentle pressure on the upper eyelid (picture 1)
- The eyelid will evert to reveal the upper tarsal conjunctiva. The FB may be large enough to be seen easily (picture 2)
- With a gentle upward movement, remove the FB using a moistened cotton bud. It may be necessary to use a needle if it has embedded
- If the FB cannot be seen, examine the eye again using a torch and magnification to ensure it is not missed
- On completion of the sub-tarsal examination and removal of FB, ask the patient to look up and the eyelid will return to its normal position
- Examine the rest of the eye for further particles
- If a corneal abrasion has resulted, instil antibiotic eye drops or ointment and apply a firm eye dressing, using two pads (a bandage may be added), for 24 hours (pictures 3 and 4).

**Review the eye after 24 hours or earlier if pain persists.**

### Finally

- Wipe needle with a swab to confirm removal of FB and show it to the patient – this will reassure him/her it has been removed
- Dispose of needle carefully in an appropriate container.

Murray McGavin



## How to remove a corneal foreign body

### Indication

- To remove superficial material from the surface of the cornea, e.g., metal fragment.

### You will need

- Slit lamp or magnification and torch
- Fluorescein strips
- Local anaesthetic drops
- Sterile No.21 gauge needle
- Sterile cotton buds
- Prescribed antibiotic eye drops or ointment
- Tape, two eye pads and bandage.

### Preparation

- Position the patient comfortably with head supported – at the slit lamp, sitting in a chair or lying down

### Method

- Instil local anaesthetic drops and fluorescein dye
- Ask the patient to look straight ahead, fix gaze and keep perfectly still
- With one hand, **gently** control the patient's eyelids
- With the other hand, support the sterile needle with two fingers and the thumb
- Approach the cornea slowly with the bevel of the needle uppermost and horizontally 'flat on' to the cornea
- Gently lift off the foreign body (FB) from the corneal surface. **Sometimes this is possible simply using a moist cotton bud and is safer practice in less skilled hands**
- Check the patient's eye, carefully everting the upper eyelid to ensure no FB's remain – a corneal abrasion may be seen
- Instil antibiotic ointment and apply a firm eye dressing, using two pads and a bandage, for 24 hours.

**If there is any resistance and the FB does not come off easily do not persist! The FB may be deeply embedded and this situation should be referred for further medical attention.**

### Finally

- Wipe needle with a swab to confirm removal of FB and show it to the patient – this will reassure him/her it has been removed
- Dispose of needle carefully in an appropriate container.

Pak Sang Lee

Cactus design and illustration Ltd.